

UC Davis

Dermatology Online Journal

Title

Unusual eruption in association with sorafenib: a case of acquired perforating dermatosis, reactive perforating collagenosis type

Permalink

<https://escholarship.org/uc/item/8b40k5kq>

Journal

Dermatology Online Journal, 24(12)

Authors

Lederhandler, Margo
Beasley, Jenna M
Brinster, Nooshin K
et al.

Publication Date

2018

DOI

10.5070/D32412042445

Copyright Information

Copyright 2018 by the author(s). This work is made available under the terms of a Creative Commons Attribution-NonCommercial-NoDerivatives License, available at <https://creativecommons.org/licenses/by-nc-nd/4.0/>

Peer reviewed

Unusual eruption in association with sorafenib: a case of acquired perforating dermatosis, reactive perforating collagenosis type

Margo Lederhandler MD, Jenna M Beasley MD, Nooshin K Brinster MD, Arielle R Nagler MD

Affiliations: New York University Langone Medical Center, The Ronald O. Perelman Department of Dermatology, New York, New York, USA

Corresponding Author: Margo Lederhandler, 240 East 38th Street, 11th Floor, New York, NY 10016, Tel: 215-964-4063, Email: margo.lederhandler@gmail.com

Abstract

The term, acquired perforating dermatoses (APD), represents a group of skin conditions that develop in adulthood and are characterized by transepidermal elimination of dermal connective tissue. This appears clinically as a papulonodule with a keratotic core. Although APD is typically associated with diabetes mellitus, chronic renal failure, and several other conditions causing generalized pruritus, there have been reports in the literature describing an association of APD with select drugs including sorafenib. We present a case of acquired perforating dermatosis in a patient with HIV and hepatocellular carcinoma undergoing treatment with sorafenib.

Keywords: acquired perforating dermatosis, perforating disease, hepatocellular carcinoma, sorafenib

Case Synopsis

A 65-year-old man with a history of HIV (well controlled on antiretroviral therapy with undetectable viral load, CD4 792), hepatitis C virus genotype 1a, and hepatocellular carcinoma presented to the dermatology clinic at the Veterans Affairs Harbor Hospital for the evaluation of painful lesions on his lower extremities, upper extremities, buttocks, and scrotum for approximately one year. Fifteen months prior to presentation, the patient was initiated on sorafenib for the treatment of hepatocellular carcinoma, as he was not a candidate for localized treatment. About two weeks later, he noted the onset of painful lesions on his legs, left elbow, buttocks, and scrotum. They began as “bumps,” and some of them resolved with a “scar” over time. The lesions were initially not pruritic;

however, those on his buttocks became pruritic in the weeks prior to presentation. He admitted to excoriating the lesions on his buttocks, but denied manipulating any of the lesions on his upper or lower extremities. He had been applying hydrocortisone 2.5% cream to affected areas, previously prescribed by the dermatology clinic at the onset of his lesions, with some relief. Aside from sorafenib, there were no new medications. There was no history of previous skin disease or similar lesions. Review of systems was notable for diarrhea and weight loss; however, he had no associated fevers, chills, night sweats, arthralgias, headaches, or confusion.

Scattered on the thighs, knees, and left elbow, there were solitary-and-grouped, brown-to-slightly-erythematous papules with a central hyperkeratotic, depressed core (**Figure 1**). On the buttocks, there were a few hyperpigmented papulonodules with a central keratotic core. In addition, there were several flesh colored papules on the scrotum.

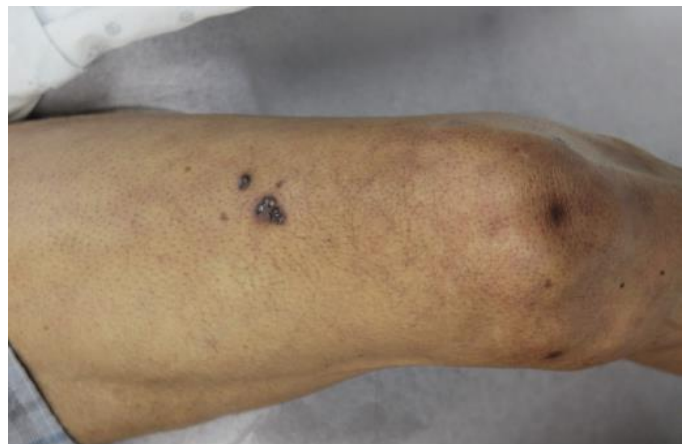


Figure 1. Left anterior thigh with several solitary and grouped, brown-to-slightly-erythematous papules with a central hyperkeratotic, depressed core.

A complete blood count demonstrated a depressed white blood cell count of 3.3/ μ L, hemoglobin 11.2g/dL, hematocrit 30.9%, platelets 142 K/ mm^3 . Coagulation studies were notable for an elevated partial thromboplastin time of 41.3 seconds. A basic metabolic panel was normal. A hepatic panel demonstrated a mildly elevated aspartate transaminase (AST) of 47 U/liter.

A 4mm punch biopsy was performed over the hyperkeratotic core and surrounding area of one of the papules on the patient's left anterior thigh. There was an epidermal invagination surrounding and forming a channel for aggregates comprised of eosinophilic fibers, neutrophils, and basophilic debris (**Figure 2**). There was an overlying parakeratotic core with adjacent epidermal hyperplasia. These findings were consistent with a diagnosis of acquired perforating dermatosis (APD).

Case Discussion

The perforating diseases are a group of cutaneous disorders characterized by transepidermal elimination of dermal connective tissue [1, 2]. Perforating diseases include reactive perforating collagenosis (RPC), elastosis perforans serpiginosa (EPS), and acquired perforating dermatosis (APD). Clinically, perforating disorders present with papulonodules containing a central keratotic core.

Perforating dermatosis arising in adulthood is referred to by some as "Kyrle disease," after the first report of a perforating disease in the literature by Kyrle in 1916 [2]. Given the various definitions of Kyrle disease in the literature, Rapini et al. resisted applying this name and instead recommended the use of APD as a catch-all term [1]. APD may be subclassified as RPC, EPS, and perforating folliculitis (PF), based on histopathologic findings [3]. In APD, lesions often occur on the lower extremities; however, they may be more widespread with a preference for extensor surfaces [2].

On histopathological examination of APD, there is a keratotic plug with focal parakeratosis overlying an atrophic epidermis. Serial sections may be required to reveal a keratotic plug in contact with the dermis and an associated inflammatory infiltrate comprised

of lymphocytes or neutrophils. There may be follicular involvement [2, 4]. In reactive perforating collagenosis, collagen fibers are seen within the plug, whereas in elastosis perforans serpiginosa, elastic fibers are seen instead [2, 4]. In APD, the keratotic plug can often not be identified as either elastin or collagen and both may be present [1].

APD has been described in the setting of multiple medical problems, most commonly in diabetes and/or renal failure. However, APD has also been described in conjunction with other causes for pruritus (liver cirrhosis, hepatocellular carcinoma among other malignancies, and insect bites), as well as with certain medications [5]. The pathogenesis of APD is not completely understood. However, it is hypothesized that trauma, such as excoriation in the setting of pruritus, may trigger the lesions via exposure of keratinocytes to advanced glycation end-product (AGE)-modified extracellular matrix proteins [6]. Accordingly, the lesions may often be seen concomitantly with prurigo nodularis. However, it is unclear if pruritus is a *cause* or a *result* of APD, given the commonality of generalized pruritus and the rarity of acquired perforating conditions [7]. An alternative theory in patients with diabetes mellitus and chronic renal failure is based on the increased fibronectin seen both in serum as

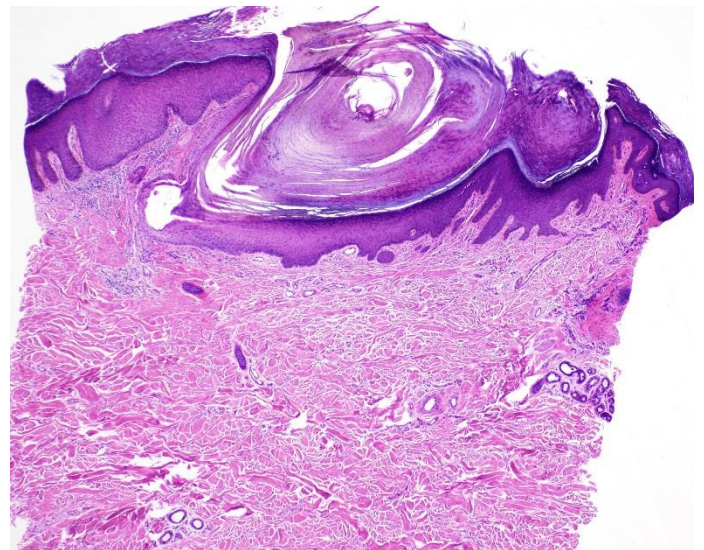


Figure 2. There is an epidermal invagination surrounding and forming a channel for aggregates comprised of eosinophilic fibers, neutrophils and basophilic debris. There is an overlying parakeratotic core with adjacent epidermal hyperplasia. H&E, 400 \times .

well as at sites of transepidermal elimination, which may be important given the role of fibronectin in binding to both type IV collagen and keratinocytes [8].

APD has also been described in the setting of exposure to certain drugs, including sorafenib. Sorafenib, an oral agent approved for the treatment of unresectable hepatocellular carcinoma, advanced renal cell carcinoma, and differentiated thyroid carcinoma, inhibits multiple kinases, resulting in prevention of tumor proliferation and angiogenesis as well as promotion of tumor apoptosis [9, 10]. Cutaneous side effects have been described in up to 90% of patients on sorafenib, with the most common being hand-foot skin reaction (HFSR) and less commonly milia, keratoacanthomas, keratosis pilaris, and acquired perforating dermatosis [9, 10]. One case series described the appearance of asymptomatic "spiny follicular hyperkeratosis" in 9 out of 43 patients within 8 months of starting sorafenib and this eruption resolved within days of discontinuing sorafenib [11]. To our knowledge, there have only been seven previously reported cases of acquired perforating disorders in the setting of sorafenib [9, 12-15]. It has been postulated that sorafenib may have an impact on the keratinocyte differentiation pathway [10], which may shed light on a theoretical pathophysiologic mechanism for sorafenib-associated disorders of keratinocyte proliferation. Nonetheless, two other case reports have demonstrated the eruption of acquired

perforating dermatoses thought to be secondary to hepatocellular carcinoma (in the absence of sorafenib). One patient was treated effectively with minocycline and the second patient saw resolution of APD upon treatment of HCC with chemoembolization [7, 16]. In our patient's case, he had several etiologic triggers for APD. He had two potentially underlying causes of pruritus, hepatocellular carcinoma and HIV. In addition, he was being treated with sorafenib.

Various treatment options have been reported in the literature, largely as small case series or individual case reports. There are no prospective controlled trials studying treatment options for APD, probably because of the rarity of the condition. When related to medications, discontinuation of the medication is typically associated with resolution of APD. Case reports of APD associated with sorafenib exposure have reported resolution once sorafenib treatment is completed. However, APD is typically not an indication to alter the appropriate length of therapy for the treatment of malignancy [13-15]. Additionally, topical corticosteroids and oral antihistamines are prescribed commonly with good response in the majority of cases [17]. Some authors have described success with oral allopurinol, topical and oral retinoids, narrow-band ultraviolet B, and photodynamic therapy [17]. Wong et al. reported treatment success with topical cantharidin in the treatment of APD, with complete clearance of treated lesions and absence of scarring [18].

References

1. Rapini RP, Herbert AA, Drucker CR. Acquired perforating dermatosis. Evidence for combined transepidermal elimination of both collagen and elastic fibers. *Arch Dermatol*. 1989;125(8):1074-8. [PMID: 2757403].
2. Rapini RP. Perforating Diseases. 3rd ed. Bologna J, Jorizzo JL, Schaffer JV, editors. Philadelphia: Elsevier Saunders; 2012.
3. Saray Y, Seckin D, Bilezikci B. Acquired perforating dermatosis: clinicopathological features in twenty-two cases. *J Eur Acad Dermatol Venereol*. 2006;20(6):679-88. [PMID: 16836495].
4. Weedon D, Strutton G, Rubin AI, Weedon D. Weedon's skin pathology. 3rd ed. Edinburgh: Churchill Livingstone/Elsevier; 2010. 1041 pp.
5. Tsuboi H, Katsuoka K. Characteristics of acquired reactive perforating collagenosis. *J Dermatol*. 2007;34(9):640-4. [PMID: 17727367].
6. Fujimoto E, Kobayashi T, Fujimoto N, Akiyama M, Tajima S, Nagai R. AGE-modified collagens I and III induce keratinocyte terminal differentiation through AGE receptor CD36: epidermal-dermal interaction in acquired perforating dermatosis. *J Invest Dermatol*. 2010;130(2):405-14. [PMID: 19865095].
7. Lee YS, Vijayasingam S, Tan YO, Wong ST. Acquired perforating dermatosis associated with recurrent hepatocellular carcinoma. *Int J Dermatol*. 1996;35(10):743-5. [PMID: 8891832].
8. Bilezikci B, Seckin D, Demirhan B. Acquired perforating dermatosis in patients with chronic renal failure: a possible pathogenetic role for fibronectin. *J Eur Acad Dermatol Venereol*. 2003;17(2):230-2. [PMID: 12705763].
9. Autier J, Escudier B, Wechsler J, Spatz A, Robert C. Prospective study of the cutaneous adverse effects of sorafenib, a novel multikinase inhibitor. *Arch Dermatol*. 2008;144(7):886-92. [PMID: 18645140].
10. Robert C, Mateus C, Spatz A, Wechsler J, Escudier B. Dermatologic

- symptoms associated with the multikinase inhibitor sorafenib. *J Am Acad Dermatol*. 2009;60(2):299-305. [PMID: 19028406].
11. Franck N, Barete S, Moguelet P, Blanchet B, Carlotti A, Ropert S, Avril MF, Frances C, Billemont B, Goldwasser F. Spiny follicular hyperkeratosis eruption: a new cutaneous adverse effect of sorafenib. *J Clin Oncol*. 2010;28(31):e640-2. [PMID: 20855839].
 12. Eberst E, Rigau V, Pageaux GP, Guillot B, Kluger N. Perforating folliculitis-like reaction related to sorafenib. *Cutis*. 2014;93(1):E8-10. [PMID: 24505595].
 13. Severino-Freire M, Sibaud V, Tournier E, Pauwels C, Christol C, Lamant L, Hautier-Mazeereuw J, Peron JM, Paul C, Bulai Livideanu C. Acquired perforating dermatosis associated with sorafenib therapy. *J Eur Acad Dermatol Venereol*. 2016;30(2):328-30. [PMID: 25209374].
 14. Minami-Hori M, Ishida-Yamamoto A, Komatsu S, Iiduka H. Transient perforating folliculitis induced by sorafenib. *J Dermatol*. 2010;37(9):833-4. [PMID: 20883372].
 15. Wolber C, Udvardi A, Tatzreiter G, Schneeberger A, Volc-Platzer B. Perforating folliculitis, angioedema, hand-foot syndrome--multiple cutaneous side effects in a patient treated with sorafenib. *J Dtsch Dermatol Ges*. 2009;7(5):449-52. [PMID: 19178612].
 16. Kilic A, Gonul M, Cakmak SK, Gul U, Demiriz M. Acquired reactive perforating collagenosis as a presenting sign of hepatocellular carcinoma. *Eur J Dermatol*. 2006;16(4):447. [PMID: 16935812].
 17. Garcia-Malinis AJ, et al. Acquired perforating dermatosis: clinicopathological study of 31 cases, emphasizing pathogenesis and treatment. *J Eur Acad Dermatol Venereol*. 2017; Accepted for publication (doi: 10.1111/jdv.14220)
 19. Wong J, Phelps R, Levitt J. Treatment of acquired perforating dermatosis with cantharidin. *Arch Dermatol*. 2012;148(2):160-2. [PMID: 22351815].