

UC Davis

Dermatology Online Journal

Title

"Angular" plasma cell cheilitis

Permalink

<https://escholarship.org/uc/item/8ft6z15p>

Journal

Dermatology Online Journal, 20(3)

Authors

da Cunha Filho, Roberto Rheingantz
Tochetto, Lucas Baldissera
Tochetto, Bruno Baldissera
et al.

Publication Date

2014

DOI

10.5070/D3203021759

Copyright Information

Copyright 2014 by the author(s). This work is made available under the terms of a Creative Commons Attribution-NonCommercial-NoDerivatives License, available at <https://creativecommons.org/licenses/by-nc-nd/4.0/>

Peer reviewed

Photo Vignette

"Angular" plasma cell cheilitis

Roberto Rheingantz da Cunha Filho¹, Lucas Baldissera Tochetto², Bruno Baldissera Tochetto², Hiram Larangeira de Almeida Jr³, Nádia Aparecida Lorencette⁴, José Fillus Netto⁵

Dermatology Online Journal 20 (3): 12

¹MD in Health, Assistant Professor, Dermatology Clinic and Ambulatory Surgery, in School of Medical Sciences, Universidade do Oeste de Santa Catarina (UNOESC), Joaçaba, Santa Catarina, Brazil.

²Student of medicine, School of Medical Sciences, Universidade do Oeste de Santa Catarina (UNOESC), Joaçaba, Santa Catarina, Brazil.

³Phd in Dermatology. Associate Professor of Dermatology at the Catholic University of Pelotas (UCPel) and Federal University of Pelotas (UFPel), Pelotas (RS), Brazil.

⁴MD, Assistant professor of Pathology in School of Medical Sciences, Universidade do Oeste de Santa Catarina (UNOESC), Joaçaba, Santa Catarina, Brazil.

⁵MD in Pathology, Adjunct professor of Basic Pathology, Universidade Federal do Paraná (UFPR), Curitiba, Paraná, Brazil.

Correspondence:

Roberto Rheingantz da Cunha Filho, MD
Avenida Santa Terezinha 243, Sala 302.
Edifício Centro Profissional, Joaçaba,
89600 000 Santa Catarina BRAZIL
E-mail: robertodermatologista@yahoo.com.br

Abstract

Plasma cell cheilitis is an extremely rare disease, characterized by erythematous-violaceous, ulcerated and asymptomatic plaques, which evolve slowly. The histological characteristics include dermal infiltrate composed of mature plasmacytes. We report a case of Plasma cell angular cheilitis in a 58-year-old male, localized in the lateral oral commissure.

Introduction

Plasma cell cheilitis is an extremely rare disease, characterized by erythematous-violaceous, ulcerated and asymptomatic plaques, which evolve slowly. The histological characteristics include a dermal infiltrate composed of mature plasmacytes. It probably represents one of the spectra of mucocutaneous plasmacytic disorders, which have not been well explained. The origin may be a benign immune reaction against known or unknown stimuli (infection, friction, trauma) [1,2]. We report a case of plasma cell angular cheilitis in a 58-year-old male, localized in the lateral oral commissure with partial regression after the topical use of pimecrolimus.

Keywords: Cheilitis; Plasma Cells; Neoplasms, Plasma Cell; Calcineurin; Immunosuppressive Agents

Case synopsis

A 58-year-old man presented with a single, asymptomatic erythematous-violaceous plaque, ulcerated in the center, which evolved slowly for 2 years (Figure 1). He had used oral antibiotics, topical antibiotics, and antifungal agents with no improvement. A complete blood count, erythrocyte sedimentation rate, IgE, serum protein electrophoresis, imunoelctrophoresis, and renal and liver function tests were normal. *Serological* screening for syphilis (VDRL), HIV, and markers for hepatitis B and C were negative. Direct smears and culture tests did not reveal fungi or yeast.

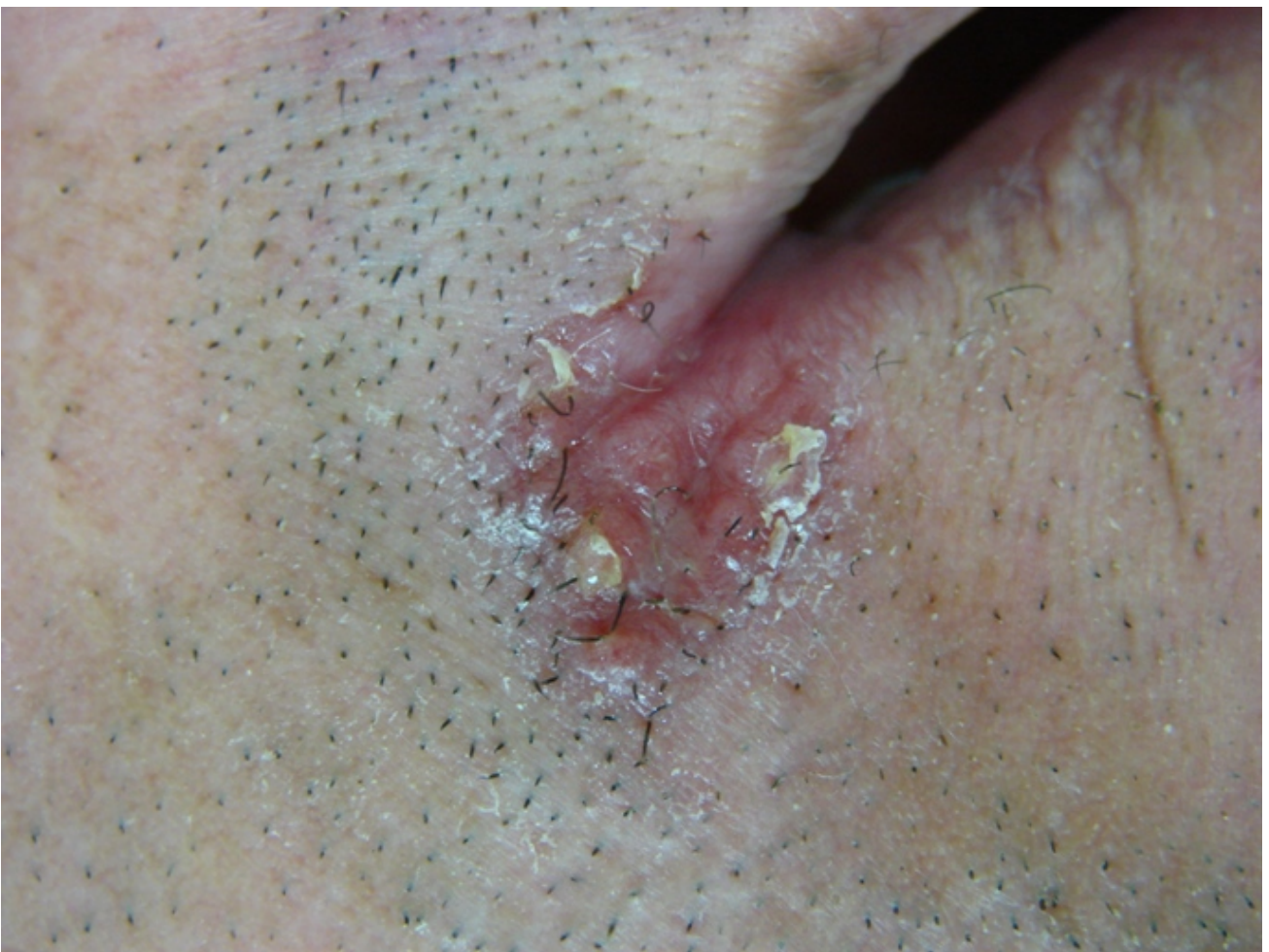

Figure 1. Erythematous-violaceous plaque, ulcerated on the corner of lip

The pathological study of an incisional biopsy showed normal epidermis and a dense dermal infiltrate composed of mature plasmacytes, lymphocytes, and some neutrophils (Figure 2). Russell bodies were occasionally observed.

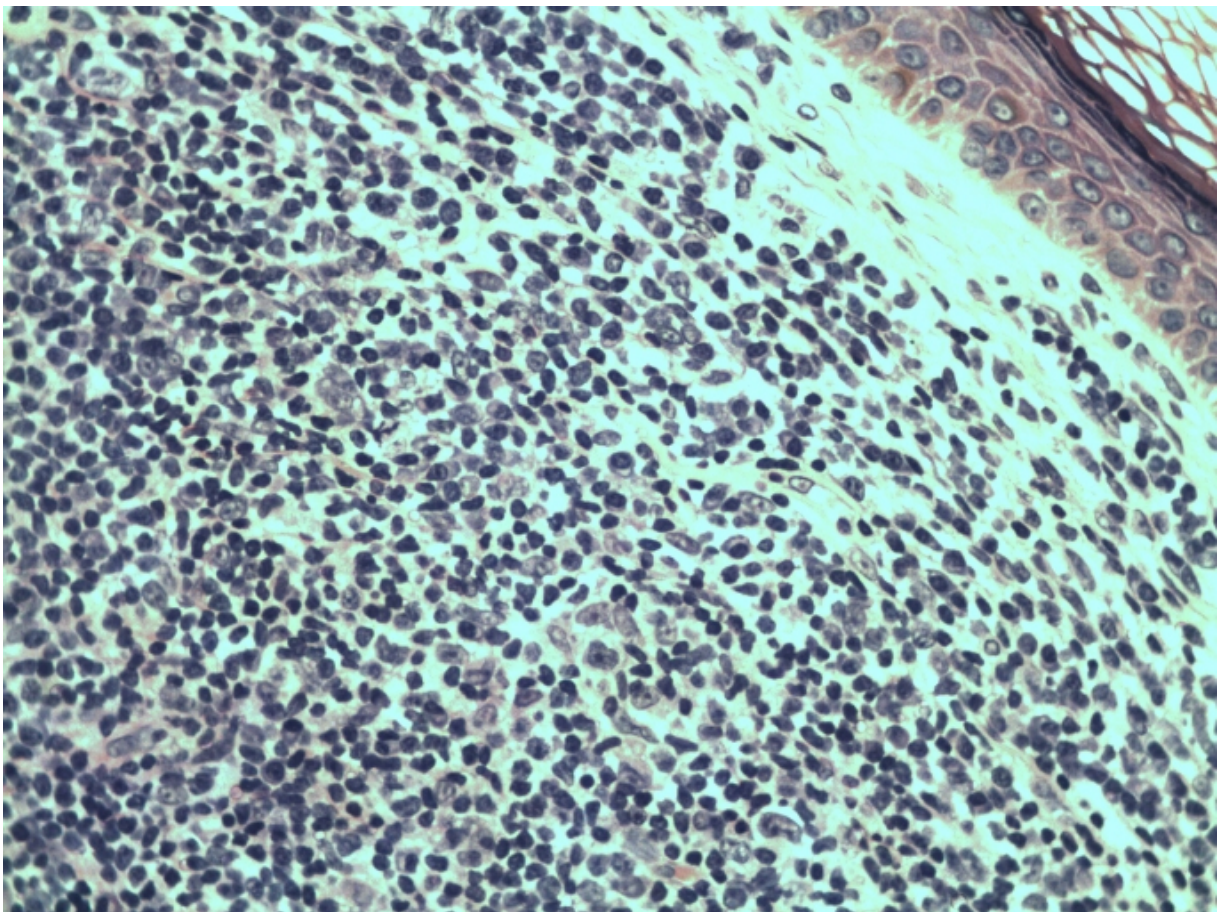


Figure 2. Dense infiltrate composed of mature plasmacytes, lymphocytes, and some neutrophils in the dermis (non atypical). Russell bodies were occasionally seen (HE, 400X).

Intralesional infiltration with triamcinolone and cryosurgery were unsuccessful. Finally, there was a partial improvement with pimecrolimus topical cream twice daily for 90 days. There were no complications. The response to pimecrolimus was good, although a total remission was not achieved, even after a follow up and treatment of 2 years (Figure 3).

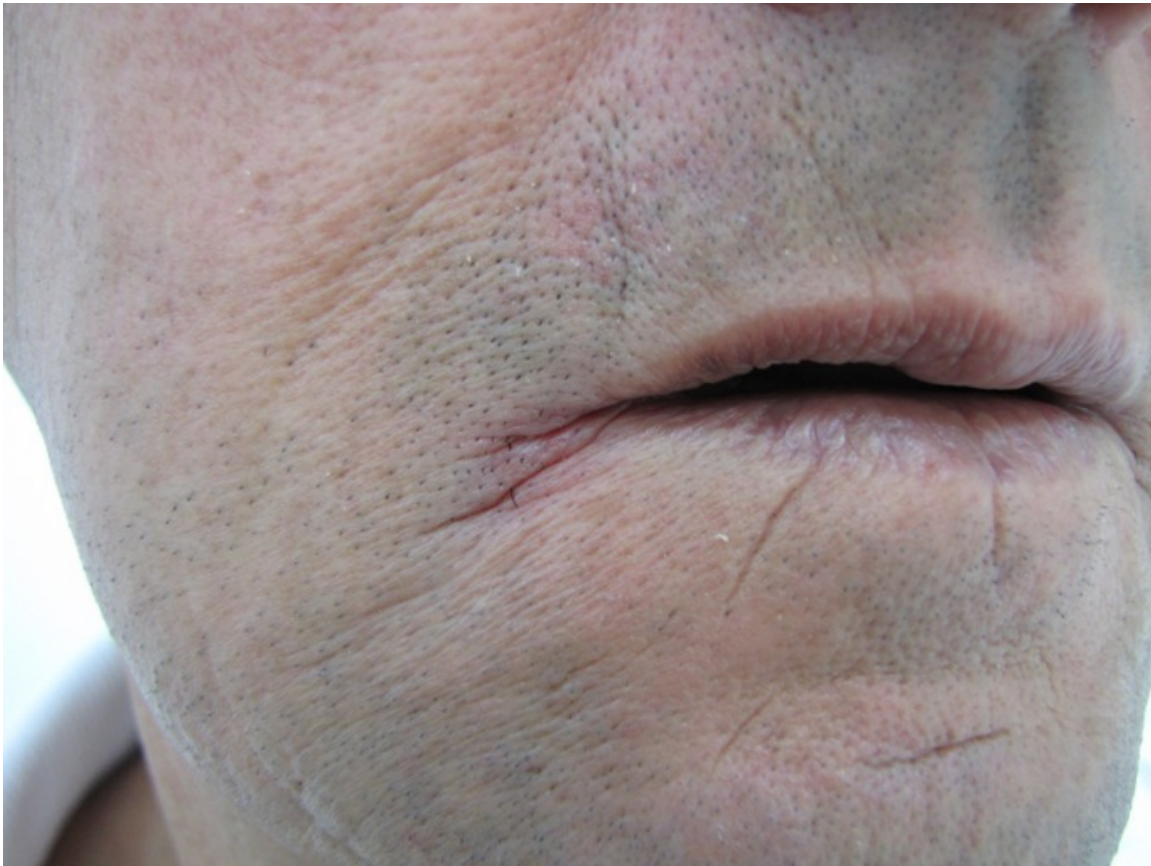

Figure 3. The lesion improved after 90 days application of pimecrolimus. Image shows partial regression after 2- years follow-up.

Discussion

Plasm cell cheilitis belongs to a heterogeneous group of rare dermatological diseases characterized by the infiltration of mature plasmocytes that affects skin or mucous membranes, especially areas of folds and the oral mucosa [1]. Many terms have been used, such as plasma cell mucositis, plasmocytosis circumorificialis, plasma cell cheilitis, and plasmocytosis mucosae [2]. This report presents this dermatitis in the lateral commissure of the lip, a location not yet reported.

The etiology of the disease is unknown. However, the influence of T cells and macrophages on cellular differentiation has been demonstrated [3]. There may be a nonspecific inflammatory response to unknown exogenous agents, such as subclinical infection, poor hygiene, trauma, friction, moisture, or *cândida* [1,4]. Gingivitis with plasmocytes may be associated with low levels of serum and secretory IgA, which would lead subclinical infections of the mucous membranes to cause the proliferation of these cells [2]. We suspect that saliva contact with the mouth angle owing to sagging skin keeps the area moist and acts as an aggravating factor. Surely there are other factors involved because the corners of the mouth over time tend to droop and sag in many elderly people, without developing plasma cell cheilitis.

Histopathological investigation reveals, infiltration of plasmocytes, some lymphocytes, and neutrophils, all mature without atypia. Acanthosis and hyperkeratosis may be present or not. Russell bodies (accumulation of immune globulin in the cytoplasm of plasma cells) are occasionally observed [2,6]. Our patient also showed these findings, corroborating the diagnosis of plasma cell cheilitis.

Because it is a rare condition, treatments are based on empirical trials or case reports with varied results. Successful treatment with fusidic acid and tacrolimus has been reported [7-9]. Systemic and topical corticosteroids, antibiotics, griseofulvin, etretinate, cyclosporine, excision, ablation with cryosurgery, CO₂ laser, electrocoagulation, and radiotherapy have also been used with varied results [2,3]. In the present case, pimecrolimus cream was applied topically twice a day, with significant but partial improvement. This drug is an immunosuppressant, calcineurin inhibitor used in the treatment of atopic dermatitis. T lymphocytes are the main cellular target of topically applied pimecrolimus. It has been shown to reduce plasmocyte infiltrates and lymphocytes [5]. It has been demonstrated that the topical administration of pimecrolimus or tacrolimus represents a promising therapeutic option for patients with cutaneous plasmocytosis [7-9].

Finally, pimecrolimus or other calcineurin inhibitors may be used as alternative treatments to reduce the intensity of the disease with few risks. However, further studies are necessary to explain the etiology and improve therapy..

References

1. Coringrato M, Belatti A, Martinetti C, Maronna E y Olivares L. Dermatitis plasmocitarias benignas, integración y revisión del tema. *Rev Argent Dermatol.* [online] 2010; 91:117.
2. Senol M, Özcan A, Aydın NE, Hazneci E, Turan N. Intertriginous plasmacytosis with plasmocanthoma: report of a typical case and review of the literature. *Int J Dermatol.* 2008 Mar;47(3):265-8. [PMID:18289329]
3. Aiba S; Tagami H. Immunoglobulinproducing cells in plasma cell orificial mucositis. *J Cutan Pathol.* 1989 Aug;16(4):207-10. [PMID:2677069]
4. Bharti R; Smith D. Mucous membrane plasmacytosis: a case report and review of the literature. *Indian Dermatol Online J.* 2003 Dec;9(5):15. [PMID:14996388]
5. Gupta AK; Chow M: Pimecrolimus: a review. *J Eur Acad Dermatol Venereol.* 2003 Set; 17(5):493-503. [PMID:12941081]
6. Rocha N; Mota F; Horta M; Lima O; Massa A; Sanches M. Plasma Cell Cheilitis. *J Eur Acad Dermatol Venereol.* 2004 Jan;18(1):96-8. [PMID:14678543]
7. Hafner C, Hohenleutner U, Babilas P, Landthaler M, Vogt T. Targeting T cells to hit B cells: successful treatment of cutaneous plasmacytosis with topical pimecrolimus. *Dermatology.* 2006;213(2):163-5. [PMID:16902298]
8. Hanami Y, Motoki Y, Yamamoto T. Successful treatment of plasma cell cheilitis with topical tacrolimus: report of two cases. *Dermatol Online J.* 2011 Feb 15;17(2):6. [PMID: 1382289]
9. Choi JW, Choi M, Cho KH. Successful treatment of plasma cell cheilitis with topical calcineurin inhibitors. *J Dermatol.* 2009 Dec;36(12):669-71. [PMID:19958456]