

# UC Davis

## Dermatology Online Journal

### Title

A 3D Ultrasound Study of Sinus Tract Formation in Hidradenitis Suppurativa

### Permalink

<https://escholarship.org/uc/item/8m93q0xc>

### Journal

Dermatology Online Journal, 19(6)

### Authors

Wortsman, Ximena  
Jemec, Gregor

### Publication Date

2013

### DOI

10.5070/D3196018564

### Copyright Information

Copyright 2013 by the author(s). This work is made available under the terms of a Creative Commons Attribution-NonCommercial-NoDerivatives License, available at <https://creativecommons.org/licenses/by-nc-nd/4.0/>

**A 3D Ultrasound Study of Sinus Tract Formation in Hidradenitis Suppurativa**

**Ximena Wortsman MD<sup>1</sup> and Gregor B.E. Jemec MD, DMedSci<sup>2</sup>**

**Dermatology Online Journal 19 (6): 6**

**<sup>1</sup>Department of Radiology and Department of Dermatology, Clinica Servet, Faculty of Medicine, University of Chile, Santiago, Chile, and <sup>2</sup>Department of Dermatology, Roskilde Hospital, Health Sciences Faculty, University of Copenhagen, Denmark.**

Correspondence

Gregor Jemec MD, DMedSci

Department of Dermatology, Roskilde Hospital,

Roskilde 4000, Denmark

E-mail: [gbj@regionsjaelland.dk](mailto:gbj@regionsjaelland.dk)

## **Abstract**

Imaging of hidradenitis suppurativa allows the study of both the lesion morphology and evolution. Hidradenitis lesions of different stages were studied using 3D ultrasound in a cross sectional pilot study. A total of 25 HS patients (18 female/ 7 male, aged 18-46 year-old) and 10 healthy controls (5 female/5 male, aged 21-49 year-old) were studied. All patients were referred by dermatologists. All examinations were performed on the right axilla and compared with both controls and the skin outside the lesional areas.

3D ultrasound images demonstrated enlargement of the deepest portion of the hair follicles in early stages. In more advanced stages dermal and subcutaneous sinus tracts were identified that were commonly connected to the base of the regional hair follicles. At the end stage of the disease, these sinus tracts were further dilated and multiple.

Ultrasound allows early detection and characterization of the morphological changes in hidradenitis, which include the variable degrees of involvement of the hair follicles and the appearance of fluid collections and sinus tracts. Knowledge of this anatomical information may allow the identification of lesions that can benefit from medical or surgical management.

**Key words: Hidradenitis Suppurativa – hair follicle – skin ultrasound – 3D reconstruction – imaging-hidradenitis ultrasound**

## **Introduction**

The non-invasive visualization of Hidradenitis suppurativa (HS) is clinically relevant to the treatment of the disease and may provide a better understanding of the pathogenic process. The HS diagnosis relies on the clinical signs and there are few reports in literature on the usage of imaging modalities on this condition.

Hidradenitis suppurativa is a recurrent or chronic inflammatory follicular skin disease, which presents with painful nodules and often suppurating lesions restricted to the intertriginous or inverse areas [1-4]. The diagnosis involves the objective identification of clinically difficult to qualify and quantify processes such as inflammation, scarring, sinus tract formation and suppuration. Thus, according to the severity of the disease the management may go from medical to surgical.

The phases of this disease are clinically classified according to Hurley in three stages (Table 1) [5]. Histologically, hidradenitis is characterized by a follicular occlusion due to keratin plugging with subsequent folliculitis and perifolliculitis. The formation of pseudocystic structures that may rupture and spread these keratinous material and inflammatory components to the surrounding tissues can be followed by the secondary destruction of the skin adnexa and sinuses formation [6].

Treatment options include medical therapy, and laser as well as conventional surgery or deroofing (7,8). Anecdotal experience suggests that incomplete removal leads to rapid recurrences; and similarly, studies have shown that more extensive surgery provides better results than limited surgery (9). No specific studies of recurrence after incomplete excision have however been conducted. Large excisions often necessitate extensive reconstructive operations, skin grafting or healing by secondary intention (10). The use of long-pulsed neodymium:yttrium-aluminium-garnet laser as well as the deroofing procedure have been advocated as a tissue-sparing methods (8,11-14).

The curative potential of medical treatment is questionable when sinus tracts occur. A dynamic in vivo method for identifying sinus tracts and assessing their evolution would therefore be of value not only in choice of therapy, but also in the study of the curative potential of medical treatments.

Recent advances in the imaging field have sequentially provided non-invasive anatomical evidence of the alterations that occur underlying the clinical lesions. Thus, we have previously shown how sonography is capable of identifying HS lesions (15,16). Color Doppler sonography can identify and measure dermal fluid collections or sinus tracts, unveil the variable degrees of inflammatory changes in the dermis (echogenicity, thickness and blood flow), register the enlargement of the hair follicles but also identify subclinical lesions (15-18). Moreover, the ultrasound study of the lymph nodes in HS has shown no significant increase of their global size when compared to healthy individuals (19).

The latest generation of ultrasound machines are enabled with softwares that allow 3D reconstructions when working with variable frequency probes that present an upper range  $\geq 15$  MHz. Thus, the reconstruction takes place by making a 5-8 seconds sweep across the lesional areas, and after a classical 2D grey scale and color Doppler ultrasound examination has been performed. The 3D image allows a more clear and understandable representation of the lesion anatomy under a conceptual framework that includes all axes in real time.

The aim of this study was to visualize a broader range of morphological characteristics of HS in 3D ultrasound reconstructions, in particular to identify early events (i.e. anatomical changes in the regions that are affected by HS) which may be potentially amendable to medical therapy, and the treatment of which, may prevent the development of sinus tracts.

## Materials and methods

We evaluated a case series of 25 HS patients (18 female/ 7 male, aged 18-46 year-old) that underwent 3D sonography in a cross-sectional retrospective study. These patients were clinically classified by certified dermatologists in different stages of the disease (Hurley I=6; Hurley II= 8; Hurley III= 11). All cases were not receiving any medication for at least 3 months before the ultrasound examination. Moreover, referrals corresponded to the first consultation of the patients in the Department of Dermatology.

All ultrasound tests were performed on the right axilla and compared with a set of images obtained from 10 healthy individuals (5 female/5 male, aged 21-49 year-old) at the same region as well as with the skin outside the lesional areas in all cases. The machines used for this study were Philips HDI 5000 (Bothell, WA); Esaote Gold MyLab 70 XVG and Twice (Genoa, Italy). The variable frequency probes used for the study were the compact linear 7 to 15 MHz, and the linear 7 to 18 MHz. The setting of the machines was calibrated on the usage of the higher frequency range for superficial structures. 3D reconstructions were highlighted by using a color filter and outline of the lesional area.

The 3D sonographic test was focused on the detection and qualification of anatomical abnormalities such as the alterations of the hair follicles (i.e. thickening and/or abnormal shape), presence of dermal thickening and/or hypoechogenicity, detection of fluid collections (i.e. anechoic or hypoechoic oval structures in the dermis and/or subcutaneous tissue), and particularly of sinus tracts (i.e. hypoechoic or anechoic band-like structures in the dermis and subcutaneous tissue).

The present study was approved by the Institutional Review Board where the sonographic examinations were performed (Clinica Servet) and the patients were examined following the Ethics principles of the Declaration of Helsinki.

## Results

Clinically, normal axillary skin provides an ultrasonographic image which is recognizable and reproducible, and allows comparison with diseased skin. (Fig. 1. In HS, several sonographic abnormalities were identified and qualified according to the severity of the disease. Sequential examinations of the 3D ultrasound images in all cases clearly showed enlargement and distortion of the base of the hair follicles, which were also present at early stages of the disease (Fig. 2).

In more advanced stages of HS the abnormalities appeared to involve the entire hair follicle, and sonographic signs of dermal inflammation (changes in echogenicity and increased thickness) were detected. Also, hypoechoic dermal and subcutaneous sinus tracts as well as fluid collections were observed in the most severe cases. Hence, in patients that presented sinus tracts and fluid collections, a connection to the base of hair follicles was detected in all cases. Other finding was the link of the base of adjacent hair follicles (Fig. 3).

Additionally to the latter sonographic features, in end stage patients these sinus tracts and fluid collections were further dilated, multiple and connected between in each other and also extended throughout the subcutaneous tissue (Fig. 4).

The Hurley staging of the patients did not exactly correspond to the sonographic images, as 2/6 of the patients clinically classified as Hurley I, sonographically had sinus tracts besides the enlargement/distortion at the bottom of the hair follicles in the vicinity (subclinical) and fluid collections ( Fig. 5). In patients clinically classified as Hurley II and III the sinus tracts were increasing in size, number and connections.

## Discussion

The anatomical information obtained in in vivo through 3D Ultrasonography clearly supports the current histological understanding of the evolution of HS, but the sonographic impression about the extension and type of the involvement appears to be more continuous and more severe than the clinical staging.

The primary event appears to be an ultrasonographic enlargement of the base of the hair follicle. Ultrasonography indicates that hair follicle distortion precedes perifollicular edema, suggesting that inflammation originates from the follicle. These findings correlate well with the histology of the disease (5,20-24). In more progressed disease, the distorted hair follicles appear linked at the deep end, suggesting that initial disease propagation occurs laterally from the bottom of the hair follicle. These lateral inter-follicular links and the involvement of the base of the hair follicles appear to be the initial steps in the formation of sinus tracts, and therefore represent the limiting step defining the curative potential of non-surgical treatment.

With more advanced disease, hair follicles are linked to fluid collections and sinus tracts spreading in a linear fashion to the subcutaneous tissue, and enlarging to crypt-like structures with progressing disease. The identification of these may aid preoperative planning by identifying deep subcutaneous extensions of the disease, and perhaps brings the possibility to separate the patients that could present a good response to medical therapy ( no sinus tracts on sonography) with the ones that can require surgery at the initial moment of consultation ( sinus tracts on sonography). Previous studies have also suggested that subclinical lesions may be identified (15), adding to the utility of the method as experience suggests that the complete removal of the lesion is necessary for optimum effect surgery.

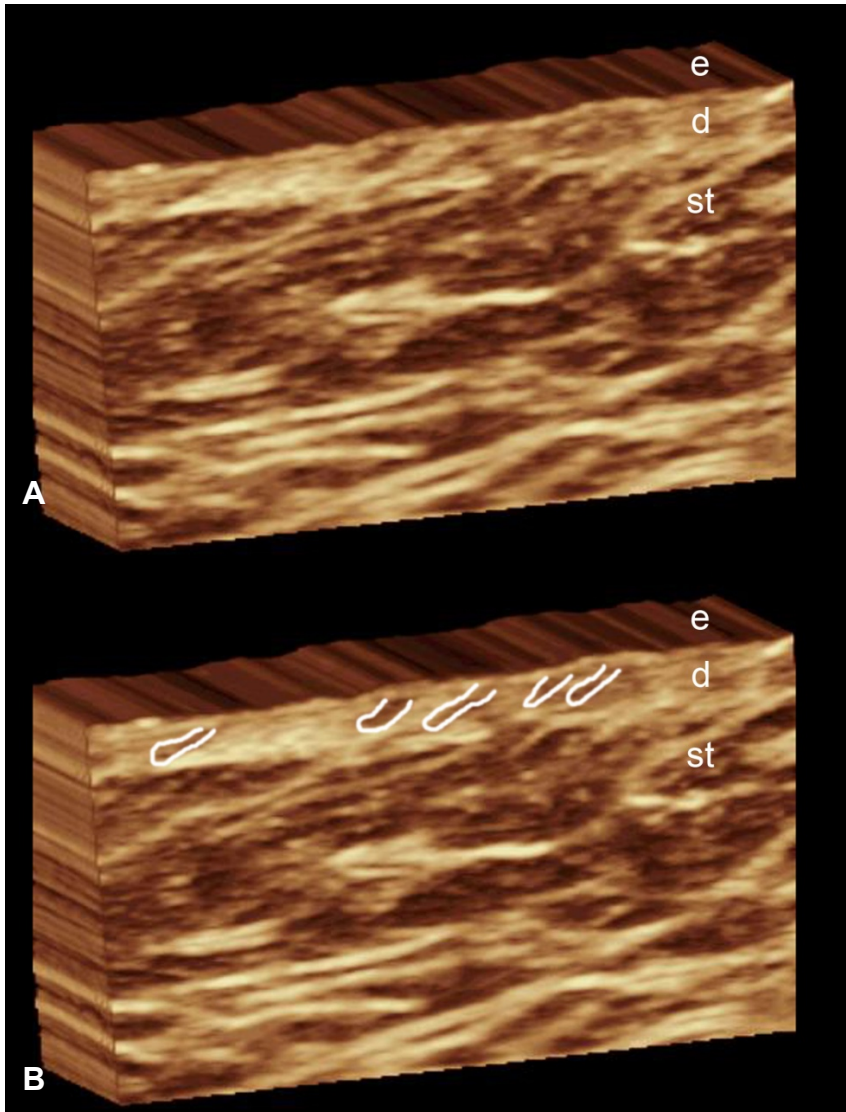
Lasly, Hurley's clinical criteria seem insufficient to provide categorical anatomical information on the underlying processes that occur in HS. The latter comment is highlighted by the fact that we found cases that were clinically classified as Hurley 1 but presented sinus tracts on sonography. Thus, most HS patients that are classified as Hurley 1 will tend to proceed to more advanced stages but this cannot be accurately predicted from the clinical findings. Furthermore, according to our observations, the ultrasound findings reveal more severe morphological changes in comparison with the clinical impression. This could leave a critical role to the widely available imaging modalities such as ultrasound. Thus, sonography can provide a missing link that may be needed to assess a more complete diagnosis based on both the anatomical criteria and the clinical findings. Additionally, more research should be done to identify which patients will be progressive and who will be stationary in disease severity. Thus, the usage of ultrasound in HS seems to require further investigation and probably a correlated clinical and sonographic scoring would be the next step that could be also followed by a quantification of the anatomical changes. 3D ultrasound images enhance the representation of these invisible to the naked-eye alterations and make them more understandable for the clinicians. Hence, the addition of ultrasound imaging to the management algorithm of HS may provide a more objective perspective and deeper insight into the complexity of this disease.

## References

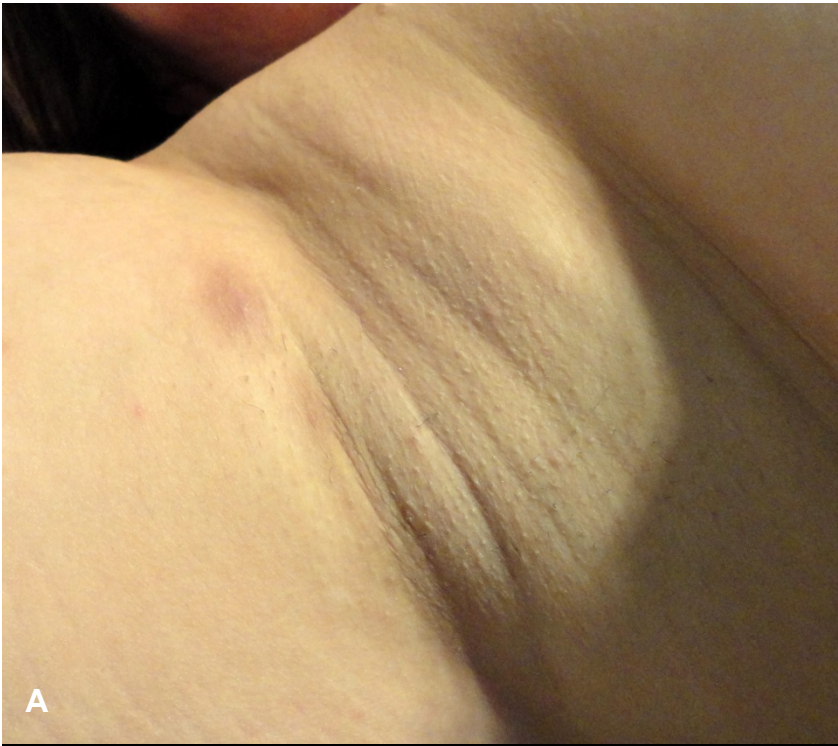1. Kurzen H, Kurokawa I, Jemec GBE, Emtestam L, Sellheyer K, Giamarellos-Bourboulis EJ, Nagy I, Bechara FG, Sartorius K, Lapins J, Krahl D, Altmeyer P, Revuz J, Zouboulis CC. What causes hidradenitis suppurativa? *Exp Dermatol* 2008; 17: 455-472. PMID: 18400064
2. Revuz J. Hidradenitis suppurativa. *J Eur Acad Dermatol Venereol*. 2009;23:985-98. PMID: 19682181
3. Jemec GB. Clinical practice. Hidradenitis suppurativa. *N Engl J Med*. 2012; 366:158-64. PMID: 22236226.
4. Girouard SD, Falk RH, Rennke HG, Merola JF. Hidradenitis suppurativa resulting in systemic amyloid A amyloidosis: a case report and review of the literature. *Dermatol Online J*. 2012;18:2. PMID: 22301039
5. Hurley HJ. Axillary hyperhidrosis, apocrine bromhidrosis, hidradenitis suppurativa and familial benign pemphigus. Surgical approach. In: Roenigk RK, Roenigk Jr HH, eds *Dermatologic surgery. Principles and practice*. 2nd ed. New York, USA: Marcel Dekker, 1996: 623-45.
6. Layton A. Pathology of hidradenitis suppurativa. In: Jemec GBS, Revuz J, Leyden J eds. *Hidradenitis Suppurativa*, Berlin, Germany, Springer 2006. 25-33.
7. Büyükaşık O, Hasdemir AO, Kahramansoy N, Cöl C, Erkol H. Surgical approach to extensive hidradenitis suppurativa. *Dermatol Surg*. 2011;37(6):835-42. PMID: 21605246
8. van der Zee HH, Prens EP, Boer J. Deroofing: a tissue-saving surgical technique for the treatment of mild to moderate hidradenitis suppurativa lesions. *J Am Acad Dermatol*. 2010;63(3):475-80. PMID: 20708472
9. Ritz JP, Runkel N, Haier J, Buhr HJ. Extent of surgery and recurrence rate of hidradenitis suppurativa. *Int J Colorectal Dis*. 1998;13(4):164-8. PMID: 9810520
10. Boyce DE, Shokrollahi K. Reconstructive surgery. *BMJ*. 2006 25;332:710-2. PMID: 16565127
11. Lapins J, Marcusson JA, Emtestam L. Surgical treatment of chronic hidradenitis suppurativa: CO2 laser stripping-secondary intention technique. *Br J Dermatol*. 1994;131:551-6. PMID: 7947209
12. Lapins J, Sartorius K, Emtestam L. Scanner-assisted carbon dioxide laser surgery: a retrospective follow-up study of patients with hidradenitis suppurativa. *J Am Acad Dermatol*. 2002;47:280-5. PMID: 12140476
13. Mahmoud BH, Tierney E, Hexsel CL, Pui J, Ozog DM, Hamzavi IH. Prospective controlled clinical and histopathologic study of hidradenitis suppurativa treated with the long-pulsed neodymium:yttrium-aluminium-garnet laser. *J Am Acad Dermatol*. 2010;62:637-45. PMID: 20227579
14. Tierney E, Mahmoud BH, Hexsel C, Ozog D, Hamzavi I. Randomized control trial for the treatment of hidradenitis suppurativa with a neodymium-doped yttrium aluminium garnet laser. *Dermatol Surg*. 2009;35:1188-98. PMID: 19438670
15. Wortsman X, Jemec GB. Real-time compound imaging ultrasound of hidradenitis suppurativa. *Dermatol Surg*. 2007;33:1340-1342. PMID: 17958586
16. Jemec GB, Gniadecka M. Ultrasound examination of hair follicles in hidradenitis suppurativa. *Arch Dermatol*. 1997;133:967-970. PMID: 9267241
17. Kelekis NL, Efstathopoulos E, Balanika A, et al. Ultrasound aids in diagnosis and severity assessment of hidradenitis suppurativa. *Br J Dermatol*. 2010;162:1400-1402. PMID: 20184586
18. Wortsman XC, Holm EA, Wulf HC, Jemec GB. Real-time spatial compound ultrasound imaging of skin. *Skin Res Technol*. 2004;10:23-31. PMID: 14731245
19. Wortsman X, Revuz J, Jemec GB. Lymph nodes in hidradenitis suppurativa. *Dermatology*. 2009;219:22-24. PMID: 19365106
20. Yu CC, Cook MG. Hidradenitis suppurativa: a disease of follicular epithelium, rather than apocrine glands. *Br J Dermatol*. 1990;122:763-9. PMID: 2369556

- 39.
40. 21. Kamp S, Fiehn AM, Stenderup K, Rosada C, Pakkenberg B, Kemp K, Dam TN, Jemec GB. Hidradenitis suppurativa: a disease of the absent sebaceous gland? Sebaceous gland number and volume are significantly reduced in uninvolved hair follicles from patients with hidradenitis suppurativa. *Br J Dermatol.* 2011;164:1017-22. PMID: 21250966
- 41.
42. 22 Jemec GB, Hansen U. Histology of hidradenitis suppurativa. *J Am Acad Dermatol.* 1996;34:994-9. PMID: 8647993
- 43.
44. 23. Jemec GB, Thomsen BM, Hansen U. The homogeneity of hidradenitis Suppurativa lesions. A histological study of intra-individual variation. *APMIS.* 1997;105:378-83. PMID: 9201239
- 45.
46. 24. von Laffert M, Stadie V, Wohlrab J, Marsch WC. Hidradenitis suppurativa/acne
47. inversa: bilocated epithelial hyperplasia with very different sequelae. *Br J*
48. *Dermatol.* 2011;164:367-71. PMID: 20831631
- 49.
- 50.
- 51.

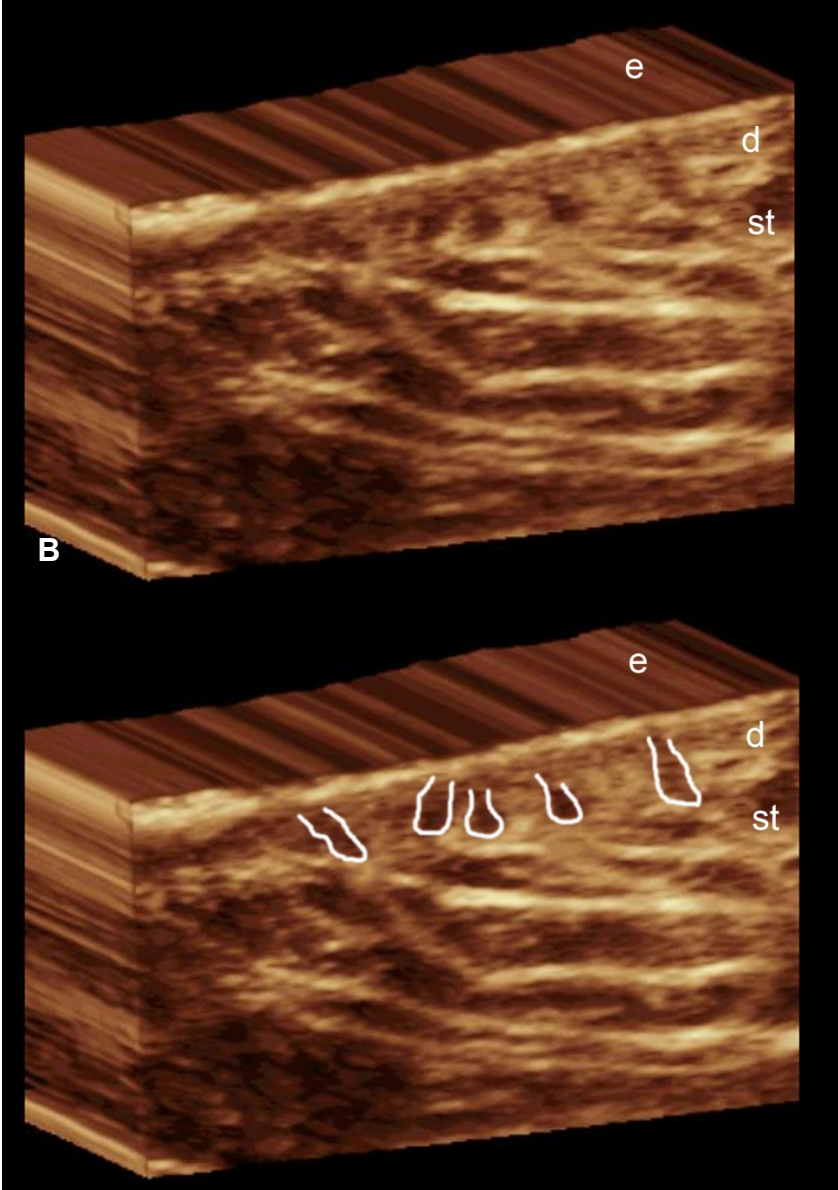
## Figure Legends



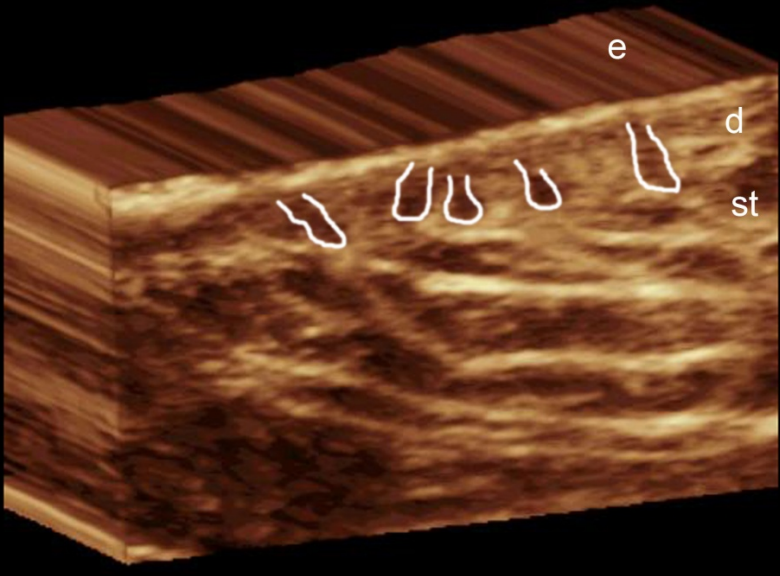
**Figure 1 (A,B).** A Normal 3 D anatomy of the skin at the axilla B. Same image with the hair follicles outlined. Abbreviations: e, epidermis; d, dermis; st, subcutaneous tissue.



A



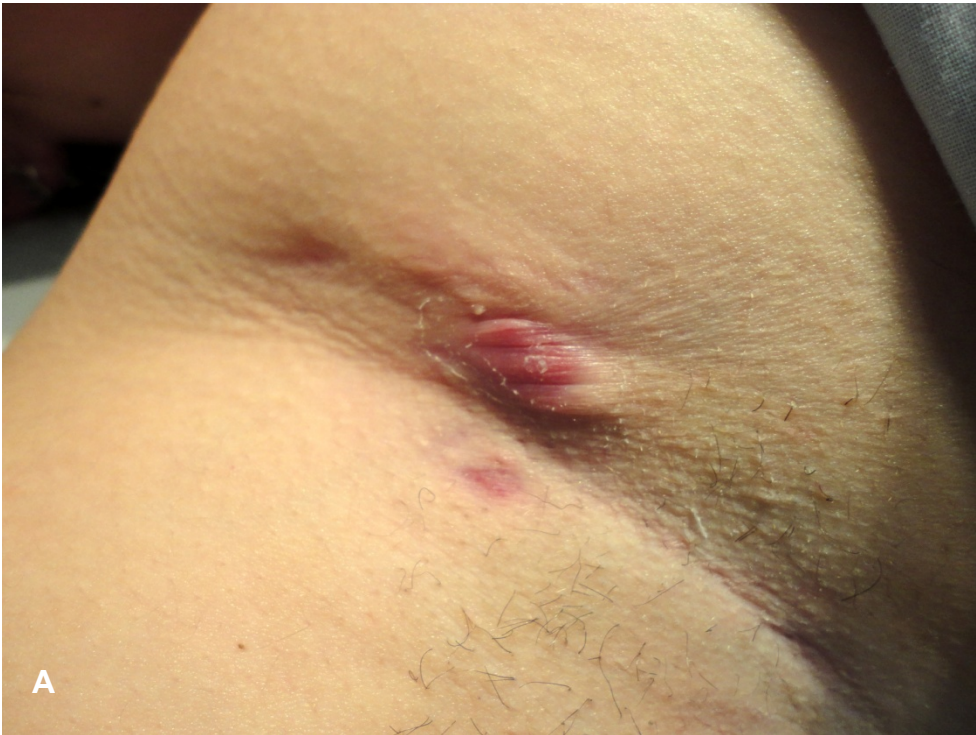B



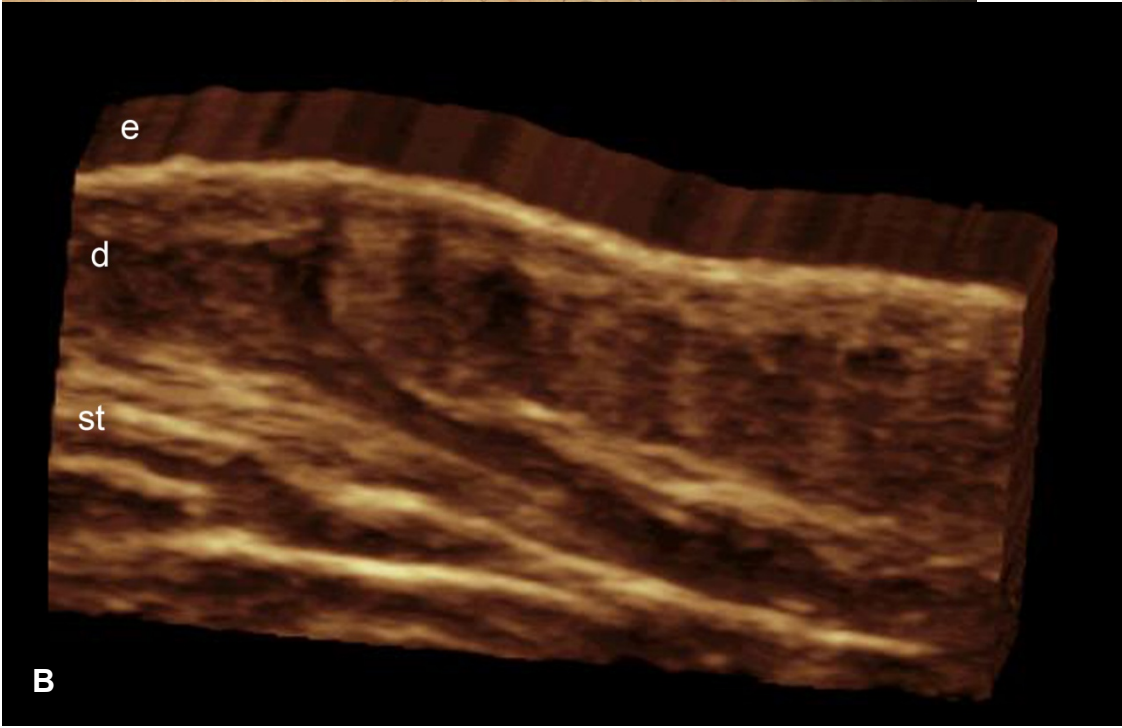
C



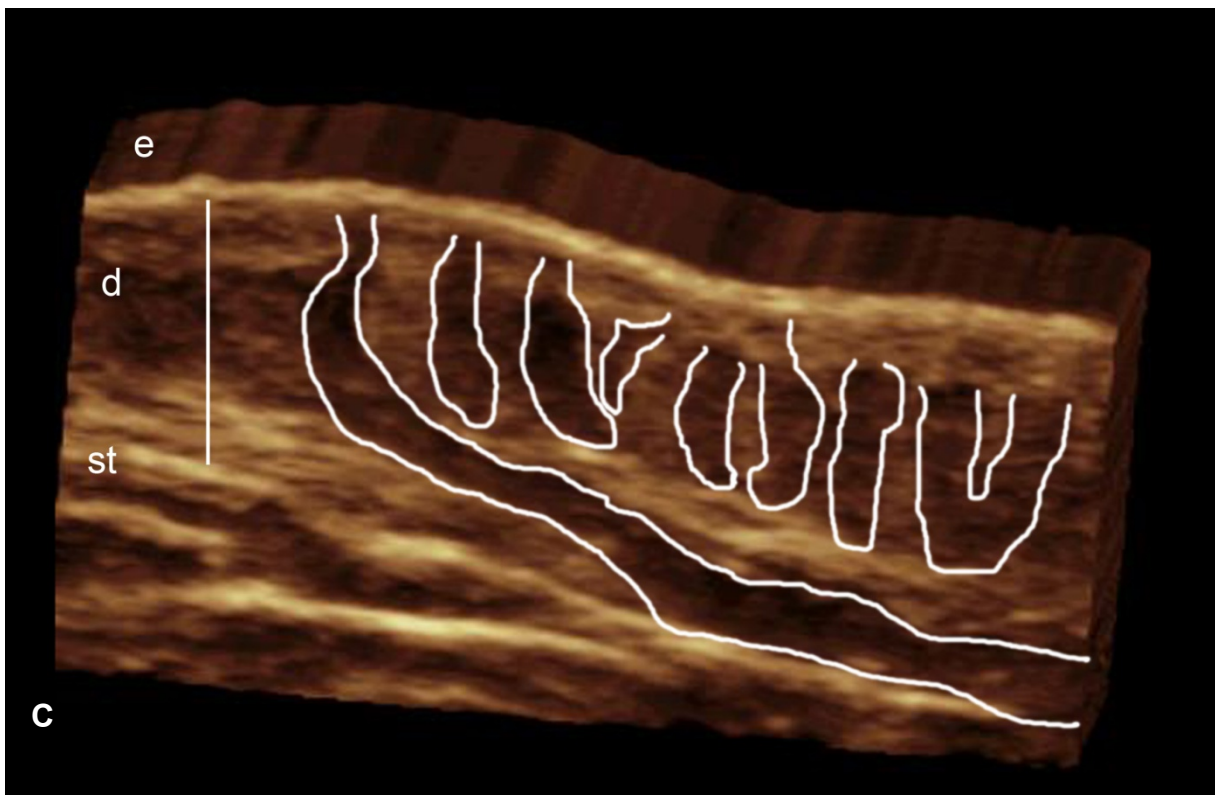
**Figure 2 (A-C). Early changes in HS. A.** Clinical image of a HS patient classified as Hurley 1. **B. and C.** 3D ultrasounds demonstrate predominant enlargement of the base of the hair follicles in the deep portion of the dermis. In fig. **C** the hair follicles have been outlined. Abbreviations: e, epidermis; d, dermis; st, subcutaneous tissue.



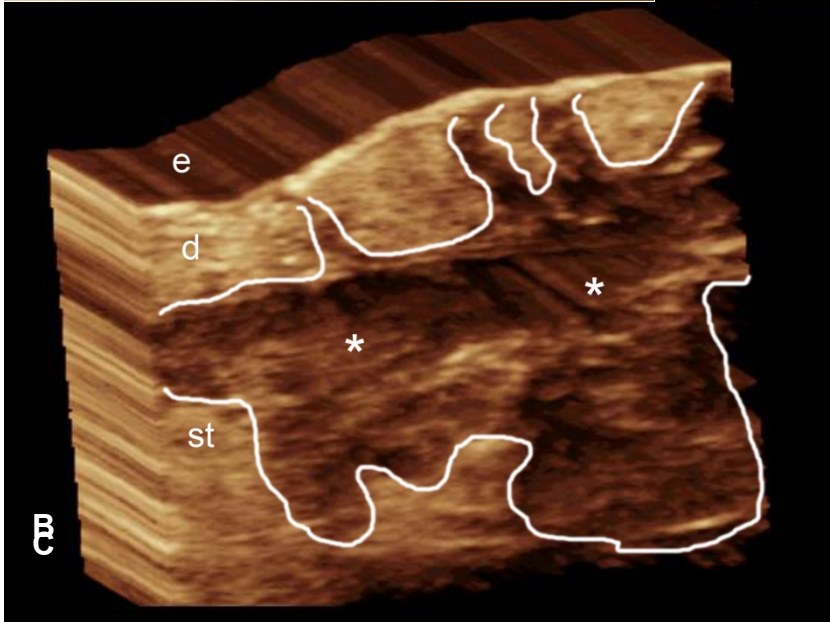
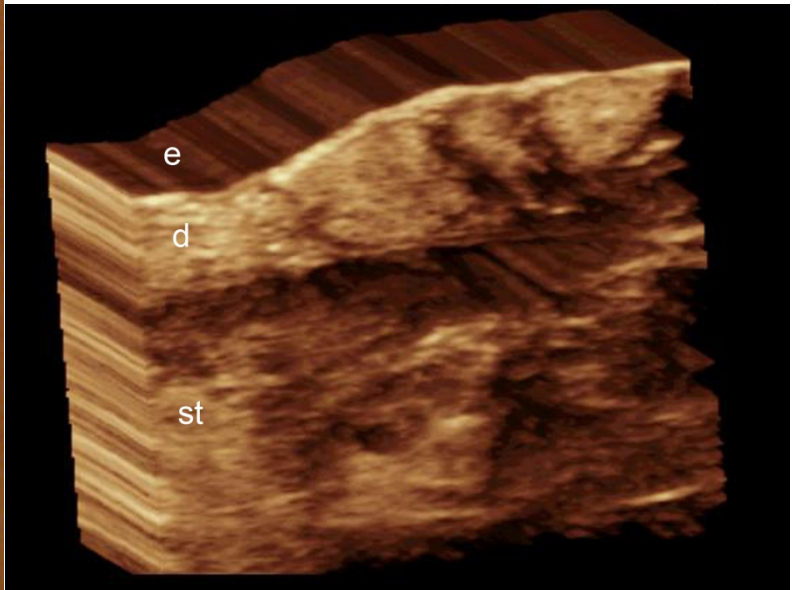
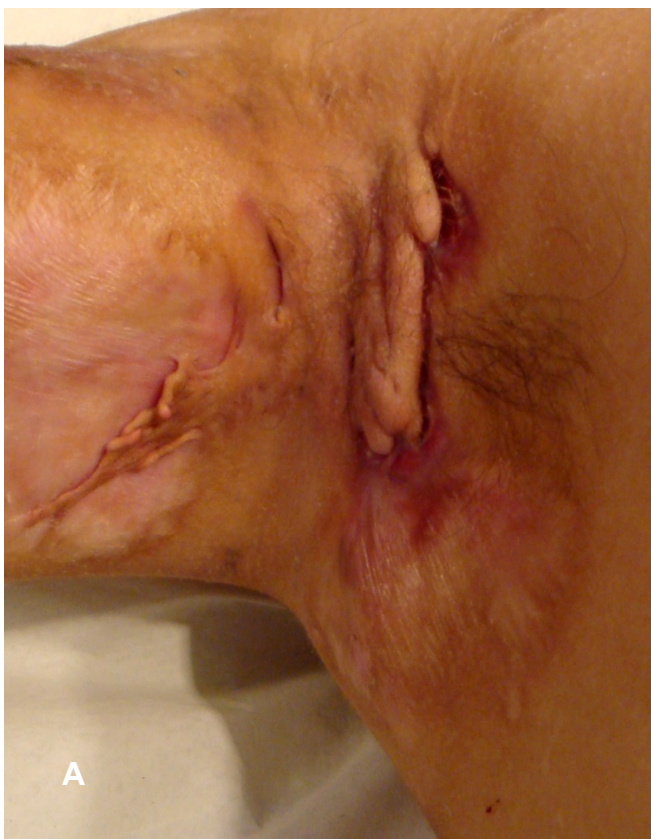A



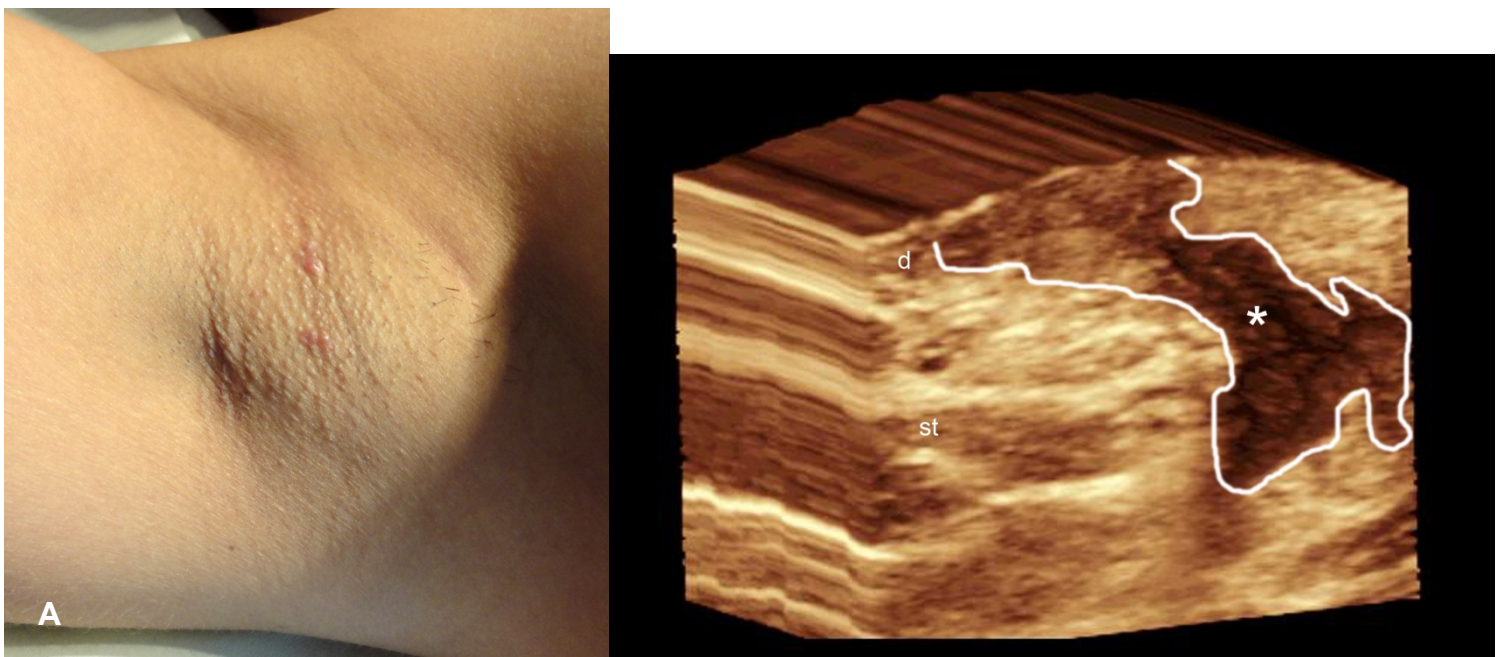
B



**Figure 3 (A-C). HS at a later stage. A.** Clinical image of a case classified as Hurley 2. **B. and C.** 3D ultrasound images show involvement of multiple hair follicles. Notice the predominant enlargement of the hair bulbs and the connection between the bulbs (right side of the image). The dermis presents increased thickness (white vertical line) and there is a long sinus tract (\*) that connects the bottom of a hair follicle with the subcutaneous tissue. In fig C. the structures have been outlined. Abbreviations: e, epidermis; d, dermis; st, subcutaneous tissue.



**Figure 4 (A-C).End-stage changes. A.** Clinical image of case classified as Hurley 3. **B. and C.** 3D ultrasound images demonstrates a hypoechoic fluid collection (\*) with echoes (debris) in the subcutaneous tissue and dermis, also connected to the base of the hair follicles. Notice the complete enlargement and connection of the base of the hair follicles (right half of the image). In fig. C. the structures have been outlined. Abbreviations: e, epidermis; d, dermis; st, subcutaneous tissue.



**Figure 5 (A-B).** Case classified as Hurley 1 shows a sinus tract on ultrasound. **A.** Clinical image of a patient classified as Hurley 1. **B.** 3D ultrasound image demonstrates a sinus tract (\* and outlined) that affects the dermis and subcutaneous tissue

### **Table 1. Hurley Classification**

I : Single or multiple abscesses or nodules without sinus tracts or scarring

II : Single or multiple recurrent abscesses or nodules with sinus tract and/or scarring, disposed in widely separated lesions

III Multiple interconnected abscesses and sinus tracts across an entire area with diffuse or near-diffuse involvement.