

UC Davis

Dermatology Online Journal

Title

Cutaneous manifestations of angioimmunoblastic T-cell lymphoma

Permalink

<https://escholarship.org/uc/item/8nt8r6k4>

Journal

Dermatology Online Journal, 25(7)

Authors

Hoskins, Sidney
Moriarty, Natalie
White, Kevin
[et al.](#)

Publication Date

2019

DOI

10.5070/D3257044807

Copyright Information

Copyright 2019 by the author(s). This work is made available under the terms of a Creative Commons Attribution-NonCommercial-NoDerivatives License, available at <https://creativecommons.org/licenses/by-nc-nd/4.0/>

Peer reviewed

Cutaneous manifestations of angioimmunoblastic T-cell lymphoma

Sidney Hoskins¹ BS, Natalie Moriarty¹ MD, Kevin White² MD, Andrea Kalus¹ MD, Andrei Shustov³ MD, Michi M Shinohara¹ MD

Affiliations: ¹Division of Dermatology, Department of Medicine, University of Washington, Seattle, Washington, USA, ²Division of Dermatology, Department of Dermatopathology, Oregon Health Sciences University, Portland, Oregon, USA, ³Division of Hematology, Department of Medicine, University of Washington, Seattle, Washington, USA

Corresponding Author: Michi Shinohara MD, 1959 NE Pacific Street, Box 356524, Division of Dermatology, University of Washington, Seattle, Washington 98195, Tel: 206-543-5290, Email: mshinoha@uw.edu

Abstract

Angioimmunoblastic T-cell lymphoma (AITL) is a rare form of non-Hodgkin lymphoma often accompanied by autoimmune and paraneoplastic phenomena. Up to 50% of patients with AITL present with skin manifestations. This case series highlights two cases of AITL presenting with unusual cutaneous findings: one with a medium-vessel vasculitis and another with a chronic urticarial eruption. Clinicians should consider AITL in the differential diagnosis of vasculitis or urticaria refractory to standard treatment.

Keywords: cutaneous ulcers, medium vessel vasculitis, urticarial eruption, angioimmunoblastic T-cell lymphoma, paraneoplastic

Introduction

Angioimmunoblastic T-cell lymphoma (AITL) was first described in 1974 [1] as a non-neoplastic hematologic condition with a propensity for skin manifestations. Now known as an aggressive peripheral T-cell lymphoma with high mortality, AITL comprises 1-2% of non-Hodgkin lymphoma cases [2]. Cutaneous manifestations are frequent in AITL and may precede systemic symptoms [3]. In a retrospective study of 52 patients with newly diagnosed AITL, 15 patients had skin manifestations at diagnosis [4]. We report two additional patients in which cutaneous manifestations preceded the diagnosis of AITL: one patient with large vasculitic ulcers accompanied by constitutional symptoms and

a neck mass, and a second patient presenting with a diffuse urticarial eruption and lymphadenopathy.

Case Synopsis

Patient 1

A 54-year-old woman presented with fatigue, malaise, swollen and painful lower legs, oral ulcers, and a neck mass. She was admitted for further workup and a few days after admission developed a petechial rash with dermal nodules and retiform purpura on her lower extremities, which subsequently coalesced into weeping, necrotic ulcers (**Figure 1A**). A computerized tomography scan of the chest showed bilateral axillary, hilar, and mediastinal lymphadenopathy and she was

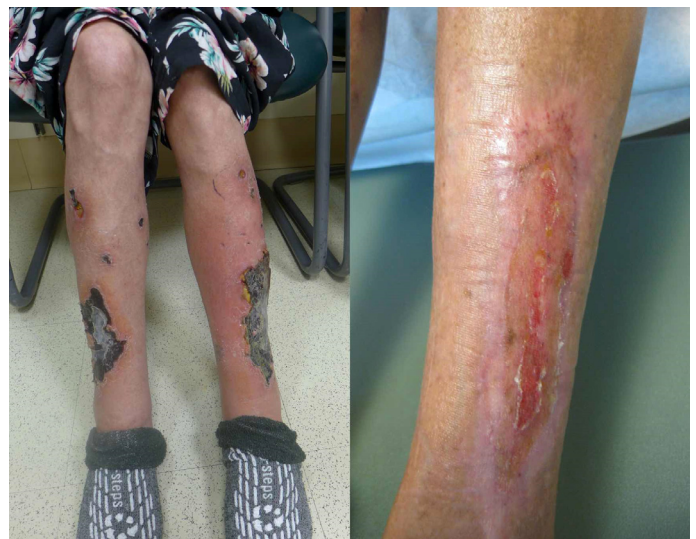

Figure 1 A) Patient 1 with necrotic leg ulcers upon presentation. **B)** Marked healing of leg ulcers in Patient 1.

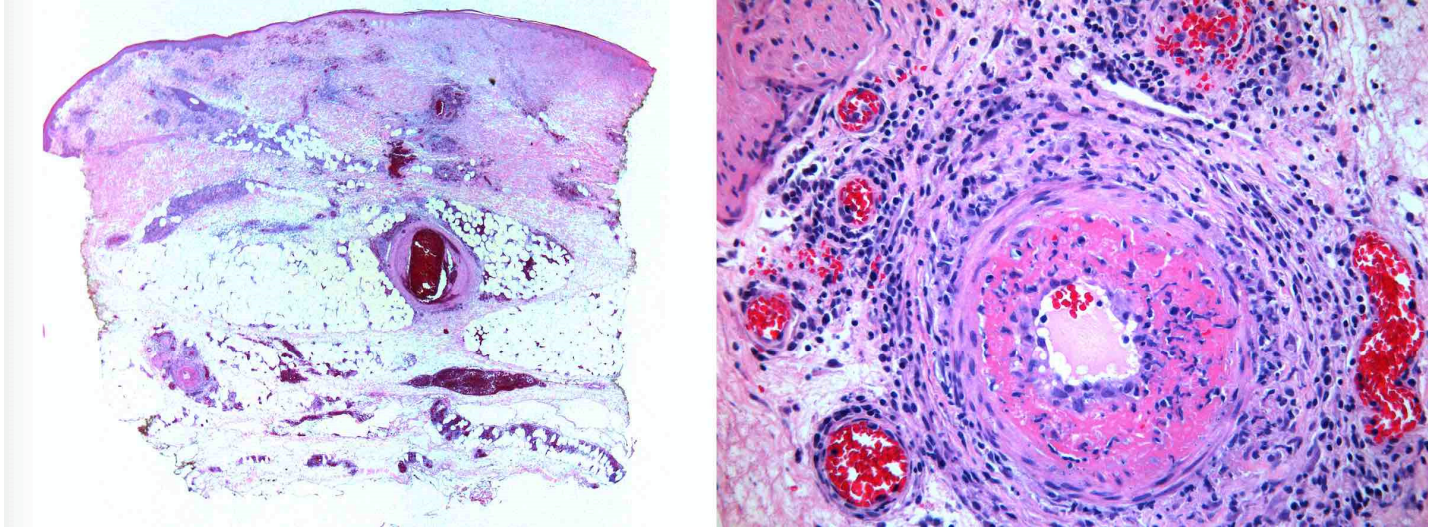


Figure 2. Skin biopsy taken from lower anterior shin of Patient 1, demonstrating medium vessel vasculitis, with thickening and fibrin deposition, neutrophils and leukocytoclastic debris in vessel walls. H&E, 1.25 \times , and 20 \times .

transferred to a regional medical center for specialty oncology care.

Laboratory data showed a total white blood cell count of 2,490 cells/ μ L, absolute neutrophil count of 770 cells/ μ L, hematocrit of 23.2%, and platelets of 200,000 cells/ μ L. The erythrocyte sedimentation rate and C-reactive protein were elevated at 76mm/hr and 79.4mg/L, respectively, whereas complement levels (C3 and C4) were low. Skin biopsy from the right lower leg showed epidermal necrosis, superficial and deep perivascular infiltrate of lymphocytes, plasma cells and neutrophils, and small to medium vessel vasculitis, with vessel wall necrosis and fibrin deposition in the upper dermis (**Figure 2**). Axillary lymph node biopsy revealed atypical infiltrating CD2, CD3, and CD5 positive lymphocytes, with partial loss of CD7 and PD1, and rare weakly-positive cells by Epstein Barr virus (EBV) in situ hybridization. T-cell receptor gene rearrangement PCR studies demonstrated a clonal T-cell population in the lymph node, further supporting a T-cell lymphoma.

Based on the combination of lymph node and bone marrow findings, the patient was diagnosed with stage III AITL, high risk (age-adjusted international prognostic index), [5], with associated paraneoplastic vasculitis. She was initially treated with prednisone (1mg/kg) and began dose-adjusted EPOCH (etoposide, prednisone, cyclophosphamide,

vincristine, doxorubicin omitted) combination chemotherapy for a total of 5 cycles. Wound care with compression and sharp debridement of the necrotic eschar was initiated. Within a few months of starting chemotherapy and meticulous wound care, the patient had marked healing of her wounds (**Figure 1B**) and underwent autologous stem cell transplant. However, 24 months later she had relapse of her AITL and died.

Patient 2

A 62-year-old woman presented with a four-month history of an urticarial eruption, cervical lymphadenopathy, weight loss, night sweats, and fevers. An allergy consultant suggested viral infection triggering urticaria; she had minimal improvement with a prednisone taper. Physical examination showed irregularly-shaped, well-demarcated, edematous plaques on her lower extremities and back (**Figure 3**), as well as cervical and axillary lymphadenopathy. Punch biopsies from the urticarial plaques showed mixed inflammatory dermal infiltrate composed of lymphocytes, eosinophils, plasma cells, and rare neutrophils (**Figure 4**). Tissue flow cytometry from the skin was negative for an atypical population.

Three days after dermatologic evaluation, the patient was admitted to the hospital for an expedited workup. Respiratory viral studies were negative. Laboratory testing showed normal

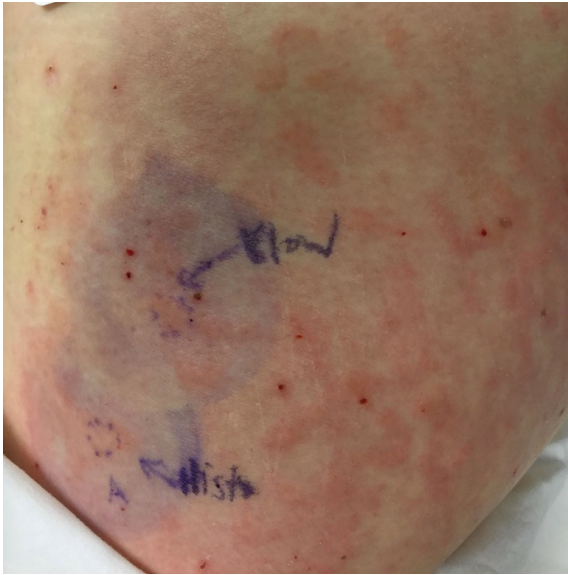


Figure 3. Urticarial eruption of Patient 2 on presentation.

complete blood count, normal erythrocyte sedimentation rate, and C-reactive protein elevation to 115.8mg/L. Axillary lymph node biopsy revealed an abnormal T-cell population expressing CD3, CD10, Bcl6, and PD1; CD2 and CD5 were normal. Epstein Barr virus in situ hybridization was positive in individual cells admixed with the T-cells. T-cell receptor gene rearrangement studies demonstrated a clonal T-cell population by PCR. PET-CT showed lymphadenopathy above and below the diaphragm and the patient was diagnosed with Stage IIIB AITL, high grade (International prognostic index), [6]. She was initiated on CEOP combination chemotherapy and received topical triamcinolone and oral hydroxyzine for symptomatic control of urticarial eruption. She was discharged from the hospital and readmitted 12 days later with progressive rash,

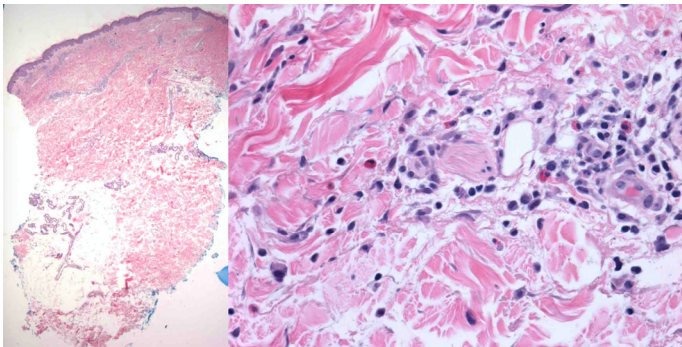


Figure 4. Histopathology of punch biopsy taken from left hip of Patient 2, demonstrating a superficial perivascular inflammatory infiltrate with numerous eosinophils, and no evidence of vasculitis. (H&E, 4x and 40x).

lymphadenopathy, and neutropenic fever attributed to malignancy after negative infectious workup. The patient was switched to BeGeV (bendamustine, gemcitabine, vinorelbine) combination chemotherapy, with resolution of her fever and urticarial dermatosis after cycle 1. The patient remains on a treatment holiday without lymphoma progression.

Case Discussion

Since its initial description over 40 years ago, the understanding of AITL has evolved from a benign reactive condition to a CD4+, CD8- peripheral T-cell lymphoma with prominent dysregulation of endothelial and B-cells. Angioimmunoblastic T-cell lymphoma is believed to initiate within EBV-infected B-cells, which proliferate after genetic rearrangement and clonal expansion. Survival of these EBV-infected B-cells likely results in stimulation of dendritic follicular T-helper cells, resulting in malignant transformation of the T-cells [7].

Skin manifestations are the presenting sign of AITL in 40-50% of patients [1-4, 7, 8], with a non-specific morbilliform eruption mimicking viral exanthem or drug eruption most commonly described [8]. Over half of patients with AITL-associated rash report pruritus [2]. This presents a diagnostic challenge in AITL owing to common misdiagnosis and subsequent delayed treatment of AITL. Other skin manifestations reported in association with AITL include nodules, erythroderma, and annular rash. Vasculitis was found in 12% of patients with AITL in 77 cases reviewed by Lachenal et al. [2]. The vasculitis associated with AITL has primarily been described as small vessel leukocytoclastic vasculitis [10, 11]. However, there are rare reports of patients presenting with cutaneous medium vessel vasculitis [1, 9, 13]. Paraneoplastic vasculitis occurs owing to antigen production resulting in increased immune complex deposition. Increased inflammatory mediators (e.g., interferon gamma, interleukins 6 and 12, TNF-alpha) and increased coagulation and angiogenesis are also believed to contribute [13]. There are a few reports of patients with AITL presenting with chronic urticarial eruptions [2, 3]. It has been suggested that infiltrating T-cells of the skin cause chronic urticaria through local release of

vasoactive molecules in AITL [3]. Lack of response to antihistamines and corticosteroids (topical or systemic) may be a clue to diagnosis. Beyond these general tenants, the pathophysiological mechanism of urticarial eruption in AITL remains largely unknown [14].

Conclusion

In summary, we report two patients presenting with atypical skin manifestations of AITL. One patient

exhibited with a medium vessel paraneoplastic vasculitis and the second patient presented with a chronic urticarial eruption. Dermatologists should be aware of AITL as a rare, EBV-associated T-cell malignancy with a propensity for skin manifestations and should consider paraneoplastic vasculitis and urticaria related to AITL in their differential diagnosis.

Potential conflicts of interest

The authors declare no conflicts of interests.

References

1. Frizzera G, Moran EM, Rappaport H. Angio-immunoblastic lymphadenopathy with dysproteinaemia. *Lancet*. 1974;1:1070-1073. [PMID: 4135245].
2. Lachenal F, Berger F, Ghesquières H, et al. Angioimmunoblastic T-cell lymphoma: clinical and laboratory features at diagnosis in 77 patients. *Medicine (Baltimore)*. 2007;86:282-292. [PMID: 17873758].
3. Kang, M., Bhatia, N., Sauder, A., & Feurdean, M. 2016. Angioimmunoblastic T Cell Lymphoma Mimicking Chronic Urticaria. *Case Rep Med*. 2016;1-5. [PMID: 26925107].
4. Li, Y., Yang, C., Mao, L., et al. Clinical characteristics of angioimmunoblastic T-cell lymphoma in China and C-reactive protein as an independent prognostic factor. *Medicine (Baltimore)*. 2017;96:e8091. [PMID: 28953629].
5. Gallamini, A., Stelitano, C., Calvi, R., et al. Peripheral T-cell lymphoma unspecified (PTCL-U): A new prognostic model from a retrospective multicentric clinical study. *Blood*, 2004;103:2474-2479. [PMID: 14645001].
6. Shipp, M., Harrington, D., Anderson, J., et al. A predictive model for aggressive Non-Hodgkin's lymphoma. *N Engl J Med*, 1993;329:983-994. [PMID: 8141877].
7. Hoffmann, J. C., Chisholm, K. M., Cherry, A., et al. An analysis of MYC and EBV in diffuse large B-cell lymphomas associated with angioimmunoblastic T-cell lymphoma and peripheral T-cell lymphoma not otherwise specified. *Hum Pathol*. 2016;48,9-17. [PMID: 26772393].
8. Seehafer J, Goldberg N, Dicken C, Su W. Cutaneous manifestations of angioimmunoblastic lymphadenopathy. *Arch Dermatol*. 1980;116:41-45. [PMID: 6444351].
9. Botros N, Cerroni L, Shawwa A, et al. Cutaneous manifestations of Angioimmunoblastic T-Cell Lymphoma: Clinical and pathological characteristics. *Am J Dermatopathol*. 2015;37:274-283. [PMID: 25794369].
10. Endo, Y., Tsuji, M., Shirase, T., et al. Angioimmunoblastic T-cell lymphoma presenting with both IgA-related leukocytoclastic vasculitis and mucous membrane pemphigoid. *Eur J Dermatol*, 2011;21;274-276. [PMID: 21489903].
11. Sugaya, M., Nakamura, K., Asahina, A., & Tamaki, K. Leukocytoclastic Vasculitis with IgA Deposits in Angioimmunoblastic T Cell Lymphoma. *J Dermatol*, 2001;28:32-37. [PMID: 11280462].
12. Ambrosio, M., Rocca, B., Ginori, A., et al. Renal infarction due to polyarteritis nodosa in a patient with angioimmunoblastic T-cell lymphoma: A case report and a brief review of the literature. *Diagn Pathol*, 2012;7; 50. [PMID: 22568881].
13. Buggiani, G., Krysenka, A., Grazzini, M., et al. Paraneoplastic vasculitis and paraneoplastic vascular syndromes. *Dermatol Ther*. 2010;23:597-605. [PMID: 21054706].
14. Loricera J, Calvo-Río V, Ortiz-Sanjuán F, et al. The spectrum of paraneoplastic cutaneous vasculitis in a defined population: Incidence and clinical features. *Medicine (Baltimore)* 2013;92:331-343. [PMID: 24145696].