

UC Davis

Dermatology Online Journal

Title

A case illustrating successful eradication of recurrent, aggressive basal cell carcinoma located in a scar with vismodegib

Permalink

<https://escholarship.org/uc/item/92k2f96t>

Journal

Dermatology Online Journal, 24(2)

Authors

Lucero, Olivia M
Fitzmaurice, Sarah
Thompson, Curtis
et al.

Publication Date

2018

DOI

10.5070/D3242038179

Copyright Information

Copyright 2018 by the author(s). This work is made available under the terms of a Creative Commons Attribution-NonCommercial-NoDerivatives License, available at <https://creativecommons.org/licenses/by-nc-nd/4.0/>

A case illustrating successful eradication of recurrent, aggressive basal cell carcinoma located in a scar with vismodegib

Olivia M Lucero¹ MD, Sarah Fitzmaurice¹ MD, Curtis Thompson^{1,2,3} MD, and Justin Leitenberger¹ MD

Affiliations: ¹Departments of Dermatology, ²Pathology and ³Biomedical Engineering, Oregon Health & Sciences University, Portland, Oregon

Corresponding Author: Justin Leitenberger MD, OHSU Center for Health & Healing, 3303 SW Bond Avenue, Suite 16D, Portland, OR 97239, Tel: 503-418-3376, Email: leitenbe@ohsu.edu

Abstract

Vismodegib is a small molecule inhibitor of the Hedgehog signaling pathway that has shown efficacy in the control of locally advanced or metastatic basal cell carcinoma, although proof of its effectiveness in the elimination of aggressive tumors is lacking. We report a case and provide complete histological evidence of a 69-year-old gentleman who presented with a recurrent, infiltrative, and sclerosing (morpheiform) basal cell carcinoma on his left upper lip that was entirely eradicated with a three-month course of vismodegib 150 mg daily. Complete histologic clearance of a tumor in a recurrent, infiltrative, and sclerosing basal cell carcinoma with vismodegib is uncommon.

Keywords: basal cell carcinoma, vismodegib, hedgehog pathway

Introduction

Genetic alterations in the sonic hedgehog (SHH) pathway leading to aberrant activation and uncontrolled basal cell proliferation underlie the majority of basal cell carcinomas (BCC), [1]. Most commonly, this involves inactivating mutations in the *Patched* tumor suppressor gene, which encodes PTCH, a transmembrane protein that inhibits the downstream effects of the protein, Smoothed (SMO). Binding of SHH to PTCH leads to dissociation

and subsequent activation of SMO, allowing for pathway activation and transcription of gene products that promote cellular proliferation. Although the majority of BCCs are effectively treated with surgery, topical chemotherapy, or radiotherapy, a minority of tumors are locally advanced and necessitate other treatment options. Vismodegib, a small molecule inhibitor of SMO, has shown efficacy in treating both primary and recurrent BCC, though its efficacy in complete clearance of recurrent or histologically aggressive tumors has been lacking [1, 2]. This is especially important given adaption of compensatory tumor survival pathways or alteration of the drug binding site that underlies tumor resistance and recurrence [3]. Highlighting the use of vismodegib as an efficacious treatment in these circumstances can provide the patient and provider with a greater number of options. In this case, we present histopathological evidence of complete tumor clearance in an aggressive, recurrent BCC following treatment with vismodegib.

Case Synopsis

A 69-year-old man with a history of hepatitis C and hypertension presented with an extensive, recurrent BCC on his left upper lip. He first noticed the BCC three years prior to presentation in the area of a traumatic scar. The patient sought care one year later and the lesion was excised. He then experienced

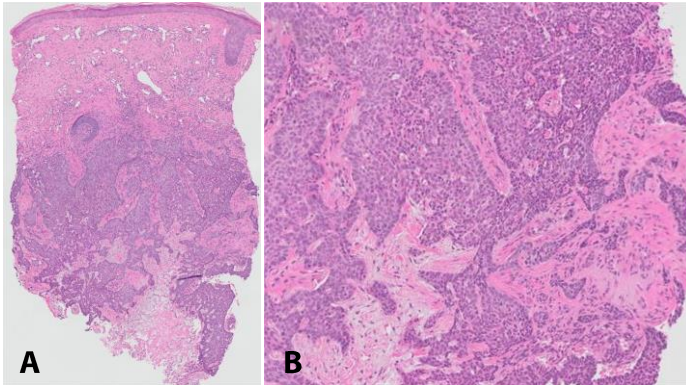


Figure 1. (A) Low (20x) and (B) high power (200x) view of biopsy specimen demonstrates recurrent infiltrative and sclerosing BCC. H&E.

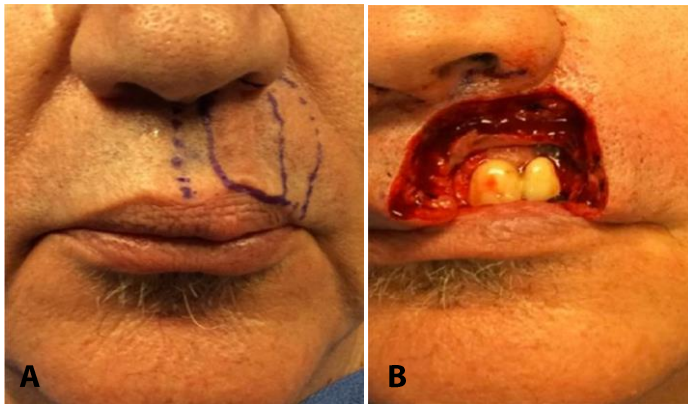

Figure 2. Site of tumor following 3 months of Vismodegib treatment with the inability to clinically differentiate scar tissue from residual tumor (A). Defect following 1 stage of Mohs micrographic surgery (B).

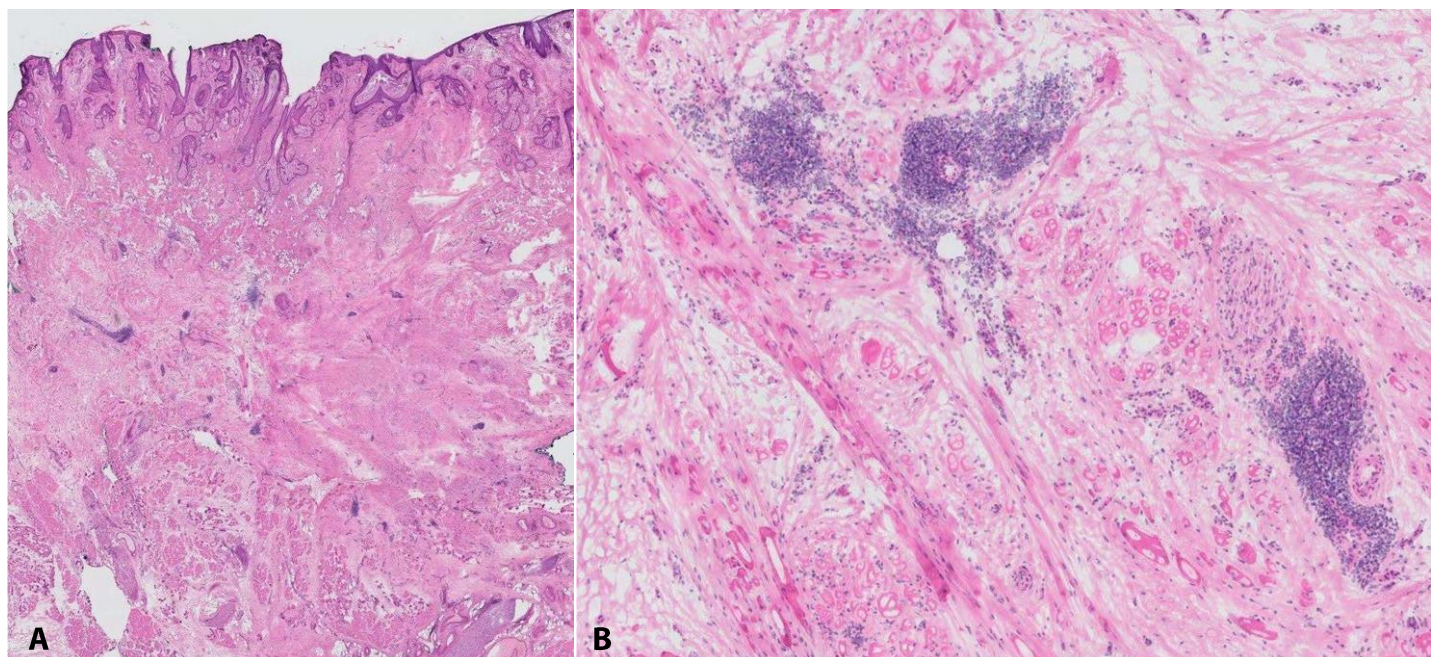


Figure 3. (A) Low power (20x) representative frozen section demonstrating scar with no residual BCC. (B) High power (200x) of the deep dermis reveals a sparse lymphocytic infiltrate.

reappearance of nodules at the same site one year following surgery. At that time, he was noted to have a 2.8 x 1.8 cm firm, hairless, violaceous, pearly plaque abutting the left nostril sill, blunting the left philtral column, and depressing the superior vermilion lip. A repeat biopsy showed an infiltrative and sclerosing-type of BCC (**Figure 1**). Given the size, location, and history of recurrence, he was started on vismodegib 150mg once per day at an outside clinic. He was noted to have an approximate 50% visual reduction in tumor mass after one month on the drug. After 3 months of treatment, there was inability to clinically differentiate scar tissue from residual tumor (**Figure 2A**). Given the size reduction, he was felt to be a surgical candidate and underwent Mohs micrographic surgery, stage 1, resulting in a 3.0cm x 2.7cm defect (**Figure 2B**). A central debulk was performed and frozen sections of the bread-loafed area demonstrated scar tissue and complete absence of residual tumor (**Figure 3**). The mapped complete circumferential peripheral and deep margins showed no involvement of residual tumor.

Case Discussion

This case demonstrates complete histological resolution after 3 months of vismodegib in a

recurrent, infiltrative and sclerosing BCC. Although vismodegib has been shown to be an effective means of BCC control, proof of its efficacy in eradicating tumors has been limited, in part by study design. A phase II study (ERIVANCE) demonstrated complete response in 13 of 63 patients with primary BCC [1]. A subsequent open label trial of inoperable BCC showed a complete response in 6 of 56 patients with locally advanced disease [2]. A recent report illustrated clinical clearance of a recurrent, infiltrative BCC following 3 months of vismodegib with biopsy 8 months after treatment revealing no residual tumor [4]. Complete response in these cases was based on biopsies, a technique flawed by potential sampling error, or clinical disappearance of visible target lesions. Whereas studies examining vismodegib as an adjuvant to Mohs have presented an opportunity for histological analysis of tumor response, no trials have shown eradication of recurrent tumors. One clinical trial by Ally et al. utilized first piece serial sectioning followed by standing cone confirmation to demonstrate complete response in 6 of 13 primary tumors; all recurrent tumors had residual BCC [5]. Another clinical trial conducted by Sofen et al. performed serial sectioning of paraffin embedded tumors with 16% of tumors demonstrating complete histological

clearance [6]. These patients, however, all had primary tumors. A case series by Alcalay et al. reported incomplete tumor resolution of three large, aggressive BCCs treated with vismodegib followed by Mohs surgery; residual tumor islands were visible in all sections [7].

Previous studies have shown that BCCs that recur after surgery often require multiple Mohs stages and are less likely to respond to vismodegib, highlighting the aggressive phenotype of these tumors [8, 9]. Our case demonstrates the potential use of vismodegib in aggressive, recurrent tumors with histological evidence of full tumor clearance, an important finding that highlights the heterogeneity in tumor survival and susceptibility to targeted therapy.

Conclusion

We demonstrate histopathologic evidence of the eradication of a recurrent morpheiform BCC following a 3-month course of vismodegib, illustrating the potential of this targeted therapy to definitively treat an aggressive BCC.

References

1. Sekulic A, Migden MR, Oro AE, Dirix L, Lewis KD, Hainsworth JD, Solomon JA, Yoo S, Arron ST, Friedlander PA, Marmur E, Rudin CM, Chang AL, Low JA, Mackey HM, Yauch RL, Graham RA, Reddy JC, Hauschild A. Efficacy and safety of vismodegib in advanced basal-cell carcinoma. *N Engl J Med.* 2012;366(23):2171-9. [PMID: 22670903].
2. Chang AL, Solomon JA, Hainsworth JD, Goldberg L, McKenna E, Day BM, Chen DM, Weiss GJ6. Expanded access study of patients with advanced basal cell carcinoma treated with the Hedgehog pathway inhibitor, vismodegib. *J Am Acad Dermatol.* 2014;70(1):60-9. [PMID: 24189279].
3. Atwood SX, Chang AL, Oro AE. Hedgehog pathway inhibition and the race against tumor evolution. *J Cell Biol.* 2012;199(2):193-7. [PMID: 23071148].
4. Zargari O, Azimi SZ, Geranmayeh S. Inoperable infiltrative basal cell carcinoma successfully treated with vismodegib. *Dermatol Ther.* 2017. Epublished ahead of print. [PMID: 28631369].
5. Ally MS, Aasi S, Wysong A, Teng C, Anderson E, Bailey-Healy I, Oro A, Kim J, Chang AL, Tang JY. An investigator-initiated open-label clinical trial of vismodegib as a neoadjuvant to surgery for high-risk basal cell carcinoma. *J Am Acad Dermatol.* 2014;71(5):904-911. [PMID: 24929884].
6. Sofen H, Gross KG, Goldberg LH, Sharata H, Hamilton TK, Egbert B, Lyons B, Hou J, Caro I. A phase II, multicenter, open-label, 3-cohort trial evaluating the efficacy and safety of vismodegib in operable basal cell carcinoma. *J Am Acad Dermatol.* 2015;73(1):99-105. [PMID: 25913533].
7. Alcalay J, Tauber G, Fenig E, Hodak E. Vismodegib as a neoadjuvant treatment to Mohs surgery for aggressive basal cell carcinoma. *J Drugs Dermatol.* 2015;14(3):219-23. [PMID: 25738842].
8. Paoli J, Daryoni S, Wennberg AM, Mölne L, Gillstedt M, Miocic M, Stenquist B. 5-Year recurrence rates of Mohs micrographic surgery for aggressive and recurrent facial basal cell carcinoma. *Acta Derm Venereol.* 2011;91:689-93. [PMID: 21681360].
9. Orengo IF, Salasche SJ, Fewkes, J, et al. Correlation of histologic subtypes of primary basal cell carcinoma and number of Mohs stages required to achieve a tumor-free plane. *J Am Acad Dermatol.* 1997;37:395-7. [PMID: 9308552].

