

UC Irvine

UC Irvine Previously Published Works

Title

Stevens-Johnson syndrome and toxic epidermal necrolysis in pregnant patients: A systematic review

Permalink

<https://escholarship.org/uc/item/9bf370vh>

Journal

International Journal of Women's Dermatology, 6(4)

ISSN

2352-6475

Authors

Sharma, Ajay N
Hedayati, Bobak
Mesinkovska, Natasha A
et al.

Publication Date

2020-09-01

DOI

10.1016/j.ijwd.2020.04.002

Peer reviewed



Review

Stevens-Johnson syndrome and toxic epidermal necrolysis in pregnant patients: A systematic review



Ajay N. Sharma BS^{a,b}, Bobak Hedayati BS^{a,b}, Natasha A. Mesinkovska MD, PhD^b,
Scott Worswick MD^{c,*}



^a School of Medicine, University of California, Irvine, CA, United States

^b Department of Dermatology, University of California, Irvine, CA, United States

^c Department of Dermatology, Keck School of Medicine, University of Southern California, Los Angeles, CA, United States

ARTICLE INFO

Article history:

Received 11 November 2019

Received in revised form 12 March 2020

Accepted 1 April 2020

Keywords:

Stevens-Johnson syndrome

Toxic epidermal necrolysis

SJS

TEN

Pregnant

Pregnancy

ABSTRACT

Background: Stevens-Johnson syndrome (SJS) and toxic epidermal necrolysis (TEN) are two of the most severe dermatologic emergencies. Although pregnant women comprise a subset of individuals at risk for SJS and TEN development, little is known with regard to outcomes and treatment.

Objective: This study aimed to conduct a systematic review to characterize the risk factors, outcomes, and treatment of SJS and TEN in pregnant patients and newborns.

Methods: A primary literature search was conducted using PubMed in September 2019, using the following search terms entered in separate pairs: *pregnant or pregnancy* and *stevens-johnson or SJS or toxic epidermal necrolysis*. Reviews, studies in a language other than English, and articles not including pregnant patients were excluded.

Results: Twenty-six articles were included for review, including a total of 177 patients. The average maternal age for a reaction was 29.9 years, gestational age was 24.9 weeks, and time to reaction after drug initiation was 27.5 days. Approximately 85% of pregnant women in this review were infected with HIV. The most common causative medications were antiretroviral therapy (90% of all cases), antibiotics (3%), and gestational drugs (2%). Of the 94 cases in which outcome data were available, the survival rates of pregnant women and newborns after delivery were 98% and 96%, respectively. Withdrawal of the offending agent and supportive care was often sufficient for treatment, but antibiotics, steroids, and intravenous immunoglobulin were implemented in some cases. Complications included preterm labor, vaginal stenosis, and vaginal adhesions.

Conclusion: Given the predominance of studies focusing on the subset of pregnant patients who are infected with HIV, SJS and TEN is most commonly reported in young patients after antiretroviral therapy, primarily nevirapine. Overall mortality is lower than that of the general population, but similar to the expected mortality rates of younger adults. Early recognition and withdrawal of the offending agent is essential to mitigate the distinct consequences of these conditions in the pregnant population.

© 2020 Published by Elsevier Inc. on behalf of Women's Dermatologic Society. This is an open access article under the CC BY-NC-ND license (<http://creativecommons.org/licenses/by-nc-nd/4.0/>).

Contents

Introduction	240
Methods	240
Results	240
Selection of studies	240
Demographics	243
Causative medications	244
Outcomes and treatment	244
Discussion	244

* Corresponding author.

E-mail address: scott.worswick@med.usc.edu (S. Worswick).

Mechanism	244
Outcomes and complications	245
Treatment	245
Limitations.....	245
Conclusion	245
Conflict of Interest	246
Funding	246
Study Approval	246
Appendix A. Supplementary data.....	246
References	246

Introduction

Stevens-Johnson syndrome (SJS) and toxic epidermal necrolysis (TEN) are two common dermatologic conditions that occur in the inpatient setting. As life-threatening conditions, SJS and TEN represent a similar disease of differing severity. Distinguishing between the two relies on the extent of epidermal detachment: SJS is defined as <10% body surface area (BSA) with epidermal detachment, TEN is defined as >30% BSA, and an SJS/TEN overlap comprises the 10% to 30% gap (Schneider and Cohen, 2017).

The incidence of SJS and TEN varies depending on geographic location, with estimates ranging from 2 to 7 cases per million people per year (Harr and French, 2010). Certain diseases, infections, and immunocompromised states raise the incidence of these conditions considerably, especially among individuals infected with HIV (Mittmann et al., 2012). The overall mortality rate among patients with SJS or TEN ranges from 10% to 50% depending on the extent of the disease, with some studies citing an average mortality rate of approximately 30% (Sekula et al., 2013).

Overwhelmingly, the two most common causes of SJS and TEN are medications and infections. Medications usually trigger the condition during the first 8 weeks of treatment, with a typical onset between 4 days and 4 weeks of onset of continuous use (Harr and French, 2010). Although many drugs have been reported to cause SJS and TEN, the most commonly involved agents in the general population include allopurinol, antiepileptic drugs, antibacterial sulfonamides, nevirapine, and oxycam nonsteroidal anti-inflammatory drugs (Mockenhaupt et al., 2008). Infections, specifically *Mycoplasma pneumoniae* infections, are the second most common trigger of SJS and TEN-like eruptions and often occur in children (Ferrandiz-Pulido and Garcia-Patos, 2013; Harr and French, 2010). Unfortunately, more than one-third of SJS and TEN cases develop without an identifiable cause, with triggers such as vaccines, vitamins, foods, and contrast medium reported as potential sources (Sassolas et al., 2010).

Treatment of these conditions is centered around prompt identification and withdrawal of the offending agent and supportive care. In a 10-year observational study, prognosis was shown to improve the earlier the causative drug was discontinued, and offending drugs with long half-lives increased the mortality rate (Garcia-Doval et al., 2000). After discontinuation, supportive care is essential, consisting of wound care, fluid and nutrition repletion, pain control, and prevention or treatment of superinfections. Although no adjunctive therapy has been established as a gold standard for SJS or TEN treatment, systemic steroids, intravenous immune globulin, cyclosporine, and tumor necrosis factor (TNF) inhibitors are all currently implemented in clinical practice with varying success.

Pregnant women comprise a subset of individuals who are at a higher risk for SJS and TEN development. The reasons for this are multifactorial, possibly due to a relative immunosuppressed state during gestation, susceptible medications, or acquired infections (Struck et al., 2010). Traditional risk factors are less applicable to

the mother and fetus when compared with the population at large, with low maternal body weight and CD4 counts >250 cells/ μ l associated with an increased incidence (Dube et al., 2013). Common offending medications during pregnancy also do not conform to expectations; certain high-risk drugs (e.g., allopurinol) are not as often prescribed in this population. These differences create an unpredictable landscape for SJS and TEN development, reducing the utility of traditional risk scores or predictive models and consequently challenging the management in this population.

Although instances of SJS and TEN in pregnant patients have been reported, the outcomes and treatment of these cases are poorly characterized in the literature. Given the high stakes of successful management, dermatologists must be prepared to treat this population. This article systematically reviews the evidence-based literature on the causes, treatment, and outcomes of SJS and TEN during pregnancy.

Methods

A systematic review was conducted in accordance with the Preferred Reporting Items for Systematic Reviews and Meta-analyses (PRISMA) guidelines. The PubMed and Cochrane databases were searched in September 2019 for all peer-reviewed articles published until September 2019 using the following search terms entered in separate pairs: *pregnant or pregnancy* and *stevens-johnson or SJS or toxic epidermal necrolysis*. Only articles in the English language concerning the study of SJS or TEN in humans were included. Case studies, case series, prospective and retrospective studies, clinical trials, and letters to the editor that recorded cases of SJS or TEN in pregnant mothers or newborns were retrieved. Review articles, articles unavailable to the study team, and clinical trial proposals were excluded. Study design and patient and outcome data were extracted and summarized from each article (Table 1).

Results

Selection of studies

The search strategy described initially revealed 175 records, which was reduced to 99 records after duplicates were removed. Articles were screened based on title, abstract, and full text as needed to determine eligibility. The inclusion criteria limited studies to those in the English language and on human subjects, as well as only case reports, case series, retrospective studies, prospective studies, and randomized controlled trials. The exclusion criteria consisted of articles reporting reactions other than SJS or TEN, reactions occurring in nonpregnant patients, and articles inaccessible to the study team.

After the exclusion of 80 studies, an additional seven records were identified through bibliographic evaluation, resulting in a total of 26 articles included in this review. Of these inclusions,

Table 1
Summary of studies reporting SJS or TEN in pregnant patients or newborns.

Year	Author	Study design	LOE	n	Age, y (mean)	GA, wk	Drug, dose	Indication	Length	Rx (TEN/SJS)*	% BSA	Tx [†]	Maternal outcome	Fetal outcome	Notes
2018	Velter	Case report	4	1	35	33	Pyrimethamine, sulfadiazine	Toxoplasmosis, seroconversion	2 wk	SJS (1)	8	Withdrawal only	Healthy	Healthy	CS
2018	De Haan	Case report	4	1	30	22	Vemurafenib	Metastatic melanoma	25 d	TEN (1)	70	Rehydration, betamethasone	Died: intracranial hemorrhage due to metastatic disease	Healthy	Vaginal
2016	Ahiskalioglu	Case report	4	1	38	32	Unknown	Unknown	Unknown	SJS (1)	Unknown	Fluid resuscitation, IVIG	Healthy	Healthy	CS
2016	Stewart	Retrospective case control study	2	169	32	Unknown	Combined antiretroviral therapy	Antiretroviral therapy	26 d	SJS, TEN (82)	Unknown	Withdrawal and replacement only	Healthy (76); died (6)	Unknown	Unknown
2015	Knight	Retrospective case control study	2	22	29	35	Nevirapine (21), efavirenz (1)	Antiretroviral therapy	16 d	SJS (16), TEN (6)	<10%, >30%	Withdrawal and replacement only	Survived, with 3 having sepsis	2 deaths (21 and 31 wk, sepsis)	CS (11) Vaginal (11)
2013	Dube	Retrospective case control study	2	6	29	Unknown	Nevirapine	Antiretroviral therapy	18–31 d	SJS (6)	<10	Withdrawal only	Healthy	Healthy	Unknown
2010	Struck	Case report	4	1	29	16	Ferritin	Prenatal	4 m	TEN (1)	75	Fluid resuscitation, topical antibiotics, blood transfusion	Healthy	Healthy	CS
2010	Shiba	Case report	4	1	26	35	Ritodrine (235 µg)	Prophylaxis for premature labor	5 wk	TEN (1)	>30	Steroid pulse therapy, oral prednisolone, fluid resuscitation	Healthy	Healthy	CS
2010	Lee	Case report	4	1	26	31	Ritodrine	Prophylaxis for premature labor	3w	TEN (1)	>30	Oral and local antibiotics, IVIG	Healthy	Healthy	CS
2010	Agboghoroma	Case report	4	1	31	20	Nevirapine	Antiretroviral therapy	6w	SJS (1)	<10	Withdrawal only	Healthy	Healthy	CS
2009	Ugburo	Case report	4	1	37	8	Artesunate, amodiaquine	Malaria	4d	TEN (1)	52	Withdrawal, fluid resuscitation, ceftriaxone	Died	Died	Septic shock
2009	Niemeijer	Case report	4	1	33	16	Unknown	Unknown	Unknown	SJS or erythema multiforme (1)	Unknown	Prednisolone, esomeprazol	Healthy	Healthy	Induced vaginal labor
2006	Rodriguez	Case report	4	1	17	22	Phenytoin	Seizure prophylaxis	3 wk	TEN (1)	60	IVIG	Healthy	Died, stillborn (TEN)	Vaginal
2006	Joao	Retrospective cohort study	2	197	26	28	Nevirapine	Antiretroviral therapy	21 d	SJS (1)	>10	Unknown	Unknown	Unknown	Unknown
2006	Marazzi	Retrospective cohort study	2	703	25	27	Nevirapine	Antiretroviral therapy	127 d	SJS (8)	>10	Withdrawal only	None due to skin	None due to skin	Unknown
2005	Shilad	Case report study	4	1	Unknown	33	Nitrofurantoin	Urinary tract infection	2 d	SJS (1)	>10	Unknown	Unknown	Unknown	CS
2004	Hitti	Randomized controlled trial	1	38	28	17	Nevirapine	Antiretroviral therapy	2 wk	SJS (38)	>10	Withdrawal only	Healthy	Healthy	Unknown
2002	Pacheco	Case report	4	1	26	30	ART (nelfinavir, lamivudine, zidovudine)	Antiretroviral therapy	3 wk	TEN (1)	60	Fluid resuscitation, oral antibiotics, prednisone	Healthy (2 weeks in ICU)	Healthy	Vaginal
1999	Yanagida	Case report	4	1	28	16	Phenobarbital, cefditoren	Unknown	Unknown	TEN (1)	Unknown	Steroid pulse therapy, oral prednisolone, fluid resuscitation	Healthy	Healthy	Vaginal

Table 1 (continued)

Year	Author	Study design	LOE	n	Age, y (mean)	GA, wk	Drug, dose	Indication	Length	Rx (TEN/SJS)*	% BSA	Tx [†]	Maternal outcome	Fetal outcome	Notes
1998	Claessens	Case report	4	1	29	29	Ritodrine	Prophylaxis for premature labor	4 wk	TEN (1)	Unknown	Withdrawal only, fluid resuscitation	Healthy (5 weeks in ICU)	Healthy	CS, twins
1985	Leung	Case report	4	1	34	Unknown	Heparin	Iliofemoral deep vein thrombosis	Unknown	TEN (1)	Unknown	Unknown	Healthy	Survived, superficial blisters and peeling, Nikolsky's sign at 48 h	Vaginal
1982	Graham-Brown	Case report	4	1	23	33	None; no infection, no drug	Unknown	Unknown	SJS (1)	>10	Fluid resuscitation, intramuscular antibiotic agents	Healthy	Healthy	CS
1964	Treichler	Case report	4	1	Unknown	6	Pyribenzamine	Headaches	4 wk	SJS (1)	>20	Erythromycin, stilbestrol, norethindrone	Healthy	Healthy	Vaginal
1964	Sweetnam	Case report	4	1	Unknown	24	Phenolphthalein, barbiturate	Unknown	16 wk	Healthy (1)	Unknown	Withdrawal only	Healthy	TEN, survived	Vaginal
1958	Vasicka	Case report	4	1	20	37	Unknown	Unknown	Unknown	SJS (1)	Unknown	Adrenocorticotropic hormone, prednisone	Healthy	Healthy	Vaginal
1954	Winston	Case report	4	1	20	26	Penicillin	Unknown	Unknown	TEN (1)	>50	Unknown	Survived, poor prognosis	Healthy	Vaginal

BSA, body surface area; CS, cesarean section; GA, gestational age; ICU, intensive care unit; IVIG, intravenous immunoglobulin; LOE, level of evidence; Rx, prescription; SJS, Stevens-Johnson syndrome; TEN, toxic epidermal necrolysis; Tx; treatment.

References: Agboghoroma et al., 2010; Ahiskalioglu et al., 2017; Claessens et al., 1998; de Haan et al., 2018; Dube et al., 2013; Graham-Brown et al., 1981; Hitti et al., 2004; Joao et al., 2006; Knight et al., 2015; Lee et al., 2010; Leung, 1985; Marazzi et al., 2006; Niemeijer et al., 2009; Pacheco et al., 2002; Rodriguez et al., 2006; Shiba et al., 2010; Shilad et al., 2005; Stewart et al., 2016; Struck et al., 2010; Sweetnam et al., 1964; Treichler and Horvath, 1964; Uguro et al., 2009; Vasicka et al., 1958; Velter et al., 2018; Winston and Mastroianni, 1954; Yanagida, 2002.

* Number in parentheses indicates exact number of SJS or TEN reactions within each sample size.

† Withdrawal of the offending agent, supportive care, and wound care were applied in all cases.

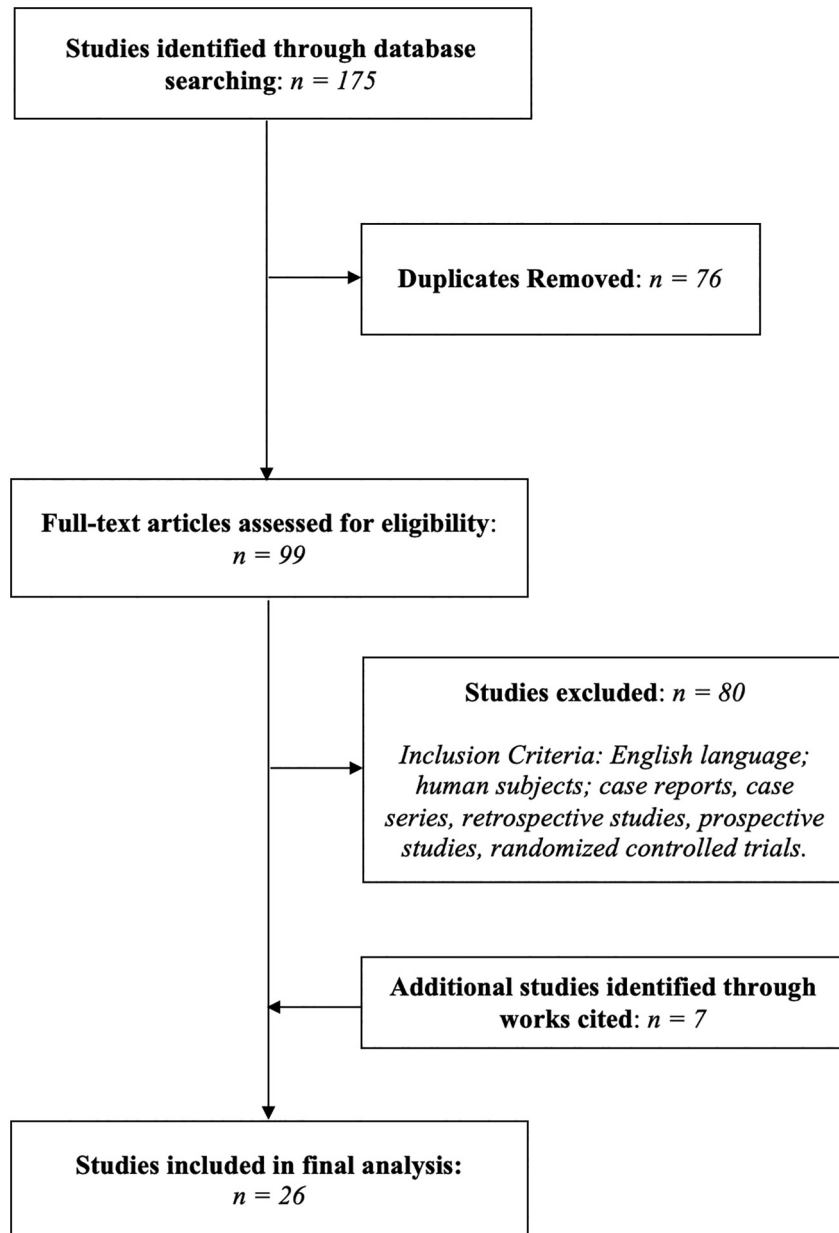


Fig. 1. Preferred Reporting Items for Systematic Reviews and Meta-analyses search for studies reporting Stevens-Johnson syndrome and toxic epidermal necrolysis in pregnant patients.

Table 2
Demographics and reactions (n = 177).

<i>Demographics (mean)</i>	
Age, year	29.9
Gestational age, weeks	24.9
Time to reaction, days	27.5
<i>Reaction (no. of cases)</i>	
Mother	
SJS	77
TEN	17
SJS/TEN unspecified	82
Healthy	1
Baby	
SJS	0
TEN	2
SJS/TEN unspecified	1

SJS, Stevens-Johnson syndrome; TEN, toxic epidermal necrolysis.

one was a randomized controlled trial, five were retrospective studies, and 20 were case studies. The selection process of these articles and their corresponding levels of evidence per the Oxford Centre for Evidence-based Medicine were recorded (Table 1; Fig. 1).

Demographics

In total, 177 cases of SJS or TEN in pregnant patients were reported (Table 2). Of this number, 157 were reported as part of a large clinical trial or study and 20 were reported independently as case studies. The average age of a pregnant woman experiencing a reaction was 29.9 years, occurring at an average gestational age of 24.9 weeks. The offending medications usually took a mean of 27.5 days before resulting in a reaction. Approximately 85% of pregnant women (151 cases) in this study were infected with HIV.

Table 3
Causative medications.

Class of drug	No. of cases
<i>Antiretroviral therapy (90%)</i>	
Unspecified regimen	83
Nevirapine	75
Efavirenz	1
<i>Antibiotics (3%)</i>	
Pyrimethamine/sulfadiazine	1
Artesunate/amodiaquine	1
Nitrofurantoin	1
Pyribenzamine	1
Penicillin	1
<i>Gestational drugs (2%)</i>	
Ritodrine	3
Ferritin	1
<i>Other (3%)</i>	
Phenobarbital	2
Phenytoin	1
Heparin	1
Vemurafenib	1
<i>Idiopathic therapy (2%)</i>	
	4

Table 4
Outcomes and treatment.

	No. of cases
<i>Outcomes</i>	
<i>Mother</i>	
Survived	92
Died	2
<i>Newborn</i>	
Survived	90
Died	4
Unknown	83
<i>Delivery</i>	
Vaginal	22
Cesarean	20
Unspecified	135
<i>Treatment</i>	
Withdrawal only	159
Fluid resuscitation	8
Antibiotics	6
Steroids	4
Intravenous immunoglobulin	2
Unknown	5

When the specific reaction was specified, the majority of cases were diagnosed as SJS (81.9%). A recent retrospective study reviewed 82 cases of SJS/TEN in pregnant patients but did not distinguish exactly which condition was found (Stewart et al., 2016). Only one report described a healthy mother giving birth to a baby who experienced a cutaneous reaction (Sweetnam et al., 1964); the two other instances of reactions in newborns occurred alongside a cutaneous reaction in the mother (Leung, 1985; Rodriguez et al., 2006).

Causative medications

The causative medications for SJS/TEN in pregnant patients can be organized into five categories: antiretroviral therapy, antibiotics, gestational drugs, other drugs, and idiopathic (Table 3). Ninety percent of all cases were reported as due to antiretroviral therapy. The majority of these cases were described in two studies alone: one large cohort study involving only patients taking antiretroviral therapy (Stewart et al., 2016) and one randomized clinical trial involving only patients infected with HIV (Hitti et al., 2004). Nevirapine was the most common single offender, causing 75 cases, whereas efavirenz was attributed only once. Multidrug regimens did not detail exactly which antiretroviral medica-

tions were administered or which one was the likely culprit, resulting in 83 cases in which the antiretroviral drug was unspecified (Pacheco et al., 2002; Stewart et al., 2016).

Antibiotics comprised 3% of all reported cases, with pyrimethamine/sulfadiazine, artesunate/amodiaquine, nitrofurantoin, pyribenzamine, and penicillin all reported once. Gestational drugs primarily consisted of ritodrine (indicated for premature labor prophylaxis) and one isolated case due to ferritin. Idiopathic and other drugs make up the remaining causes in this population. Four reports did not have an identifiable cause, and vemurafenib, heparin, and phenytoin were all reported once. Phenobarbital or an equivalent derivative caused two cases of TEN (Sweetnam et al., 1964; Yanagida, 2002).

Outcomes and treatment

Outcomes of both pregnant women and newborns were recorded, with survival defined as successful delivery and immediate postnatal course (Table 4). The time to discharge from the hospital varied among patients, ranging from days to weeks, depending on the intensity of postnatal treatment. Of the 94 pregnant patients who had outcome data available, only two did not survive. One died from septic shock secondary to a TEN superinfection and the other from intracranial hemorrhage secondary to metastatic melanoma. Similarly, of the 94 fetuses who had outcome data available, four did not survive. Two died of sepsis after birth, one was stillborn, and the last died in utero along with the mother. Delivery method was unspecified in the majority of cases, but when recorded, 20 women underwent a cesarean section (CS) and 22 women delivered vaginally.

With regard to treatment, withdrawal of the offending drug was enacted in every recorded case of SJS or TEN during pregnancy. This single intervention was adequate in 159 patients; no additional therapy was needed in these cases aside from standard wound care, fluid and electrolyte repletion, and pain control. When further management was necessary, fluid resuscitation, antibiotics (intravenous and/or oral), steroids, and intravenous immunoglobulin (IVIG) were all implemented. The treatment regimen in five cases was not recorded.

Discussion

SJS and TEN during pregnancy has historically been poorly defined, despite the potential harms to both the mother and fetus. This systematic review revealed 177 cases in this population, caused by a myriad of drugs, treated by various regimens, and resulting in a range of outcomes.

Mechanism

The mechanism of SJS and TEN development in pregnant women remains unknown; however, possible explanations exist. Immune changes that occur during pregnancy create a relative state of immunosuppression, likely increasing the risk of these skin reactions (Gupta et al., 2016). These complex immunomodulatory deviations may explain the rare but existing cases of SJS without an identifiable trigger (Graham-Brown et al., 1981; Niemeijer et al., 2009). In a 2013 matched case-control study, pregnancy increased the risk of developing SJS 14-fold (Dube et al., 2013).

The fact that the majority of patients experiencing SJS or TEN were infected with HIV is a clear reflection of the population subsets in these studies. Mechanistically, patients with HIV have been demonstrated to have an increased risk of developing drug reactions because of the loss of CD4+CD25+ T cells, skin-protective regulatory leukocytes (Yang et al., 2014). Multiple large cohort studies

specifically assessed outcomes in only pregnant patients with HIV, resulting in an overall distribution of offending medications biased toward antiretroviral therapy (Dube et al., 2013; Knight et al., 2015; Stewart et al., 2016).

Nevirapine, the most common offending drug in those receiving antiretroviral therapy, is a staple in management especially in the developing world, where most of the included studies were conducted. Prior to 2012, HIV-infected patients in countries such as South Africa were accelerated into a nevirapine-containing regimen after initiation with efavirenz owing to possible teratogenicity associated with efavirenz (Dube et al., 2013). As prescriptions of nevirapine increased, so did the incidence of SJS and TEN, leading to a reversal of this practice and replacement with efavirenz as the drug of choice in pregnant patients in South Africa. This proved successful: The incidence decreased from 3.4 cases per year between 2006 and 2013 to 0 cases per year between 2013 and 2015 (Stewart et al., 2016; White et al., 2018).

Mother-to-fetus transmission of SJS or TEN is rare. Only three cases of newborns experiencing a cutaneous reaction were reported, with one case arising from a completely asymptomatic mother (Leung, 1985; Rodriguez et al., 2006; Sweetnam et al., 1964). Proposed, but unproven, explanations for transmission of SJS or TEN are multifaceted (Rodriguez et al., 2006). Pregnant patients given sulfa drugs or anticonvulsants may transmit inadequately detoxified reactive metabolites to the fetus, inducing an immune response that leads to SJS or TEN. In two of the fetal cases of TEN found in this review, the offending maternal drug was an antiepileptic (phenytoin, phenobarbital). Alternatively, there may be a familial genetic predisposition to developing SJS or TEN marked by specific human leukocyte antigen types or a transfer of maternal drug-specific cytotoxic T cells across the placenta. If placental transfer occurs, there is likely no meaningful alteration of the physical structure of the placenta. In a retrospective series of 22 pregnant patients with SJS or TEN, placenta–birth weight ratio, a marker of fetal and placental growth balance, remained within the normal limits in all patients (Knight et al., 2015).

Outcomes and complications

Of the 94 pregnant women for whom outcome data were available, the mortality rate was extremely low for all SJS and TEN cases combined (2.1%). This lower-than-expected rate may be due to several factors. In such a critical patient population, dedicated intensive nursing and supportive care are likely more strictly implemented (Knight et al., 2015). Additionally, studies have shown that pregnant patients are often on fewer concurrent medications, indicating fewer comorbidities. In this review, the average age of all patients was 29.9 years. When applying a severity-of-illness score for toxic epidermal necrolysis (SCORTEN), age ≥ 40 years is considered a large risk factor, automatically classifying our patient population as low risk on the basis of age (Fouchard et al., 2000).

In addition to SCORTEN, the ABCD-10 criteria (i.e., age, bicarbonate, cancer, dialysis, and 10% BSA) have been developed as an alternative risk prediction model for in-hospital mortality among patients with SJS and TEN (Noe et al., 2019). However, similar to SCORTEN, this model has not been validated in pregnant patients. Specifically, one study estimated the mortality rate of SJS in patients aged 18 to 29 years as 0.98% and 20 to 39 years as 4.02%, very similar to the mortality rate reported in this review (Ezaldein et al., 2017). As a predictor of mortality for SJS/TEN, age > 39 years has been shown to have significant odds ratios of 1.46 (40–59 years), 2.51 (60–79 years), and 2.60 (≥ 80 years), supporting the claim that a low mortality in the pregnant population is heavily influenced by the mother's age (Hsu et al., 2016).

Among the 94 newborns for whom outcome data were available, the mortality rate was similarly low (4.3%), but higher than

that of the mothers. Previously reported mortality rates for SJS and TEN in pregnant patients have ranged from 14% to 19% (Knight et al., 2015; Struck et al., 2010). In all four fetal deaths, the mother was diagnosed with TEN, with an affected BSA of $>30\%$, 52%, and 60% (Knight et al., 2015; Rodriguez et al., 2006; Uguro et al., 2009). However, given the rarity of maternal transmission of SJS or TEN to the newborn, it is difficult to conclude whether the severity of the maternal reaction is related to poorer fetal outcomes.

In this review, delivery method data were recorded in 42 cases, revealing a CS rate of 47.6%. The risk of premature labor was the overriding indication for CS in this population; fetal stress due to maternal disease was commonly observed (Claessens et al., 1998). After delivery, long-lasting effects of genital mucosal surface necrosis can be observed in up to 28% of all patients (Knight et al., 2015). The most common consequences found in this review were vaginal stenosis and adhesions, which frequently acted as indications for CS (Struck et al., 2010). Other complications included vaginal and vulvar adenosis, both of which may lead to dyspareunia and infertility. Each of these chronic genital complications is also seen in the nonpregnant population. Despite these potentially permanent sequelae, a history of SJS does not absolutely preclude pregnancy because evidence of successful deliveries has been reported years after treatment for SJS (El Daief et al., 2014; Kratzert et al., 1988).

Treatment

Treatment in this patient population generally mimics that of the population at large, yet there are some special considerations. The most critical aspect of SJS or TEN treatment is prompt identification and withdrawal of the causative agent. Over 90% of cases in this review resolved with withdrawal of the offending agent alone (159 of 172 cases; five cases had unknown treatment). No absolute guidelines exist regarding adjunctive therapy in SJS or TEN, and current standards of care use systemic corticosteroids, IVIG, cyclosporine, plasmapheresis, or anti-TNF monoclonal antibodies, particularly etanercept (Kumar et al., 2018). Only six cases in the literature used one of these treatments, with four cases implementing steroids and two cases using IVIG. Anti-TNF monoclonal antibodies are a relatively recent advancement in SJS and TEN treatment, gaining popularity in the late 2010s (Paradisi et al., 2014). Only four studies concerned SJS or TEN in pregnant patients after 2015; thus, there are no examples of anti-TNF agents applied to treat this population.

A 2011 systematic review found that the four main treatment modalities in children were IVIG, steroids, dressings with or without surgical debridement, and supportive treatment alone (Del Pozzo-Magana et al., 2011). In the three cases of newborn cutaneous reactions in this study, one case resolved with supportive and wound care alone (Sweetnam et al., 1964), and the other two cases did not explicitly document treatment of the newborn. With this limited sample size, it is difficult to draw any additional conclusions regarding evidence-based treatment for newborns.

Limitations

There are limitations in this study, which primarily stem from the inconsistent reporting between studies. Not every report specified BSA involvement, treatment regimen, maternal or fetal outcome, or delivery method. The largest study included in this review (Stewart et al., 2016) contributed >80 cases without details on gestational age, BSA, or maternal/fetal outcome. Given the majority of studies focusing on patients who were infected with HIV, the causative factors reported may be specific to this patient

population. In this review, only English-language articles were considered, which perhaps resulted in a language bias.

Conclusion

SJS and TEN development in pregnant patients has historically been poorly characterized. The most common causative medications were antiretroviral drugs, primarily nevirapine, a manifestation of multiple large studies focusing specifically on pregnant patients infected with HIV or those taking antiretroviral therapy. Evidence reveals a lower-than-expected mortality rate in mothers, likely due to a younger patient population with fewer comorbidities, and rare transmission of disease to the fetus.

Rates of CS are high in this subset of patients, with permanent consequences including vaginal stenosis, adhesions, and adenosis. Withdrawal of the offending agents is typically sufficient treatment, emphasizing the importance of early diagnosis and identification. Although additional studies in the form of large-scale, randomized, clinical trials are needed to better delineate treatment, this systematic review provides a framework for managing this population.

Conflict of Interest

None

Funding

None

Study Approval

The author(s) confirm that any aspect of the work covered in this manuscript that has involved human patients has been conducted with the ethical approval of all relevant bodies.

Appendix A. Supplementary data

Supplementary data to this article can be found online at <https://doi.org/10.1016/j.ijtd.2018.11.001>.

References

- Agboghroma CO, Uwaezuoke T, Jibrin PG. Stevens-Johnson syndrome associated with nevirapine use in an HIV-positive pregnant woman: a case report. *West Afr J Med* 2010;29(3):187–9.
- Ahiskalioglu A, Yayik AM, Erguney OD, Ahiskalioglu EO, Alici HA. Combined spinal-epidural anaesthesia for urgent caesarean section in a parturient with Stevens-Johnson syndrome. *Int J Obs Anesth* 2017;30:78–9.
- Claessens N, Delbeke L, Lambert J, Matthieu L, Lafaire C, Van Marck E. Toxic epidermal necrolysis associated with treatment for preterm labor. *Dermatology* 1998;196(4):461–2.
- El Daief SG, Das S, Ekekwe G, Nwosu EC. A successful pregnancy outcome after Stevens-Johnson syndrome. *J Obs Gynaecol* 2014;34(5):445–6.
- Dube N, Adewusi E, Summers R. Risk of nevirapine-associated Stevens-Johnson syndrome among HIV-infected pregnant women: The Medunsa National Pharmacovigilance Centre, 2007–2012. *S Afr Med J* 2013;103(5):322–5.
- Ezaldein H, Totonchy M, Chow C, Samuel A, Ventura A. The effect of comorbidities on overall mortality in Stevens-Johnson Syndrome: an analysis of the Nationwide Inpatient Sample. *Dermatol Online J* 2017;23(4):23(4).
- Ferrandiz-Pulido C, Garcia-Patos V. A review of causes of Stevens-Johnson syndrome and toxic epidermal necrolysis in children. *Arch Dis Child* 2013;98(12):998–1003.
- Fouchard N, Bertocchi M, Roujeau JC, Revuz J, Wolkenstein P, Bastuji-Garin S. SCORTEN: A severity-of-illness score for toxic epidermal necrolysis. *J Invest Dermatol* 2000;115(2):149–53.
- Garcia-Doval I, LeCleach L, Bocquet H, Otero XL, Roujeau JC. Toxic epidermal necrolysis and Stevens-Johnson syndrome: Does early withdrawal of causative drugs decrease the risk of death? *Arch Dermatol* 2000;136(3):323–7.
- Graham-Brown RA, Cochrane GW, Swinhoe JR, Sarkany I, Epsztejn LJ. Vaginal stenosis due to bullous erythema multiforme (Stevens-Johnson syndrome). Case report. *Br J Obs Gynaecol* 1981;88(11):1156–7.
- Gupta L, Martin A, Agarwal N, D'Souza P, Das S, Kumar R, et al. Guidelines for the management of Stevens-Johnson syndrome/toxic epidermal necrolysis: an Indian perspective. *Indian J Dermatol Venereol Leprol* 2016;82(6):603.
- de Haan J, van Thienen JV, Casaer M, Hannivoort RA, Van Calsteren K, van Tuyl M, et al. Severe adverse reaction to vemurafenib in a pregnant woman with metastatic melanoma. *Case Rep Oncol* 2018;11(1):119–24.
- Harr T, French LE. Toxic epidermal necrolysis and Stevens-Johnson syndrome. *Orphanet J Rare Dis* 2010;5:39.
- Hitti J, Frenkel LM, Stek AM, Nachman SA, Baker D, Gonzalez-Garcia A, et al. Maternal toxicity with continuous nevirapine in pregnancy: results from PACTG 1022. *J Acquir Immune Defic Syndr* 2004;36(3):772–6.
- Hsu DY, Brieve J, Silverberg NB, Silverberg JI. Morbidity and mortality of Stevens-Johnson syndrome and toxic epidermal necrolysis in United States adults. *J Invest Dermatol* 2016;136(7):1387–97.
- Joao EC, Calvet GA, Menezes JA, D'Ippolito MM, Cruz ML, Salgado LA, et al. Nevirapine toxicity in a cohort of HIV-1-infected pregnant women. *Am J Obs Gynecol* 2006;194(1):199–202.
- Knight L, Todd G, Muloiwa R, Matjila M, Lehloeny R. Stevens-Johnson syndrome and toxic epidermal necrolysis: Maternal and foetal outcomes in twenty-two consecutive pregnant HIV-infected women. *PLoS One* 2015;10(8):e0135501.
- Kratzert K, Marks F, Antoine C, Brescia RJ, Parodneck L, Young BK. Pregnancy post-Stevens-Johnson syndrome: case report and review of the literature. *Obstet Gynecol* 1988;72(3 Pt 2):447–50.
- Kumar R, Das A, Das S. Management of Stevens-Johnson syndrome-toxic epidermal necrolysis: looking beyond guidelines! *Indian J Dermatol* 2018;63(2):117–24.
- Lee JH, Yang HJ, Yang BK, Lee SY, Park C, Kim DH. Anesthetic management for emergent cesarean section in a patient with toxic epidermal necrolysis - a case report. *Korean J Anesth* 2010;59(Suppl):S167–71.
- Leung A. Toxic epidermal necrolysis associated with maternal use of heparin. *JAMA* 1985;253(2):201.
- Marazzi MC, Germano P, Liotta G, Guidotti G, Loureiro S, da Cruz Gomes A, et al. Safety of nevirapine-containing antiretroviral triple therapy regimens to prevent vertical transmission in an African cohort of HIV-1-infected pregnant women. *HIV Med* 2006;7(5):338–44.
- Mittmann N, Knowles SR, Koo M, Shear NH, Rachlis A, Rourke SB. Incidence of toxic epidermal necrolysis and Stevens-Johnson syndrome in an HIV cohort: an observational, retrospective case series study. *Am J Clin Dermatol* 2012;13(1):49–54.
- Mockenhaupt M, Viboud C, Dunant A, Naldi L, Halevy S, Bouwes Bavinck JN, et al. Stevens-Johnson syndrome and toxic epidermal necrolysis: Assessment of medication risks with emphasis on recently marketed drugs. The EuroSCAR-study. *J Invest Dermatol* 2008;128(1):35–44.
- Niemeijer IC, van Praag MC, van Gemund N. Relevance and consequences of erythema multiforme, Stevens-Johnson syndrome and toxic epidermal necrolysis in gynecology. *Arch Gynecol Obs* 2009;280(5):851–4.
- Noe MH, Rosenbach M, Hubbard RA, Mostaghimi A, Cardones AR, Chen JK, et al. Development and validation of a risk prediction model for in-hospital mortality among patients with Stevens-Johnson syndrome/toxic epidermal necrolysis-ABCD-10. *JAMA Dermatol* 2019;155(4):448–54.
- Pacheco H, Araujo T, Kerdel F. Toxic epidermal necrolysis in a pregnant, HIV-infected woman. *Int J Dermatol* 2002;41(9):600–1.
- Paradisi A, Abeni D, Bergamo F, Ricci F, Didona D, Didona B. Etanercept therapy for toxic epidermal necrolysis. *J Am Acad Dermatol* 2014;71(2):278–83.
- Del Pozzo-Magana BR, Lazo-Langner A, Carleton B, Castro-Pastrana LI, Rieder MJ. A systematic review of treatment of drug-induced Stevens-Johnson syndrome and toxic epidermal necrolysis in children. *J Popul Ther Clin Pharmacol* 2011;18:e121–33.
- Rodriguez G, Trent JT, Mirzabeigi M, Zaulyanov L, Bruce J, Vincek V. Toxic epidermal necrolysis in a mother and fetus. *J Am Acad Dermatol* 2006;55(5 Suppl):S96–8.
- Sassolas B, Haddad C, Mockenhaupt M, Dunant A, Liss Y, Bork K, et al. ALDEN, an algorithm for assessment of drug causality in Stevens-Johnson syndrome and toxic epidermal necrolysis: comparison with case-control analysis. *Clin Pharmacol Ther* 2010;88(1):60–8.
- Schneider JA, Cohen PR. Stevens-Johnson syndrome and toxic epidermal necrolysis: a concise review with a comprehensive summary of therapeutic interventions emphasizing supportive measures. *Adv Ther* 2017;34(6):1235–44.
- Sekula P, Dunant A, Mockenhaupt M, Naldi L, Bouwes Bavinck JN, Halevy S, et al. Comprehensive survival analysis of a cohort of patients with Stevens-Johnson syndrome and toxic epidermal necrolysis. *J Invest Dermatol* 2013;133(5):1197–204.
- Shiba M, Kido K, Umezawa K, Higaki H, Matsumoto S, Taguchi A, et al. Erythematous and bullous rash strongly indicating toxic epidermal necrolysis associated with the use of intravenous ritodrine hydrochloride. *J Obs Gynaecol Res* 2010;36(3):676–80.
- Shilad A, Predanic M, Perni SC, Houlihan C, Principe D. Human immunodeficiency virus, pregnancy, and Stevens-Johnson syndrome. *Obs Gynecol* 2005;105(5 Pt 2):1254–6.
- Stewart A, Lehloeny R, Boule A, de Waal R, Maartens G, Cohen K. Severe antiretroviral-associated skin reactions in South African patients: a case series and case-control analysis. *Pharmacoepidemiol Drug Saf* 2016;25(11):1313–9.
- Struck MF, Illert T, Liss Y, Bosbach ID, Reichelt B, Steen M. Toxic epidermal necrolysis in pregnancy: case report and review of the literature. *J Burn Care Res* 2010;31(5):816–21.

- Sweetnam WP, Barlow AJ, Denniss RG. Intrapartum toxic epidermal necrolysis. *Arch Dis Child* 1964;39:517–8.
- Treichler HP, Horvath PN. Erythema multiforme exudativum (Stevens-Johnson syndrome) in early pregnancy: report of a case. *Obs Gynecol* 1964;24:309–12.
- Ugburo AO, Ilombu CA, Temiye EO, Fadeyibi IO, Akinolai OI. Severe idiosyncratic drug reaction (Lyells syndrome) after ingesting dihydroartemisinin. *Niger J Clin Pr* 2009;12(2):224–7.
- Vasicka AI, Lin TJ, Das BK. Erythema multiforme exudativum (Stevens-Johnson syndrome) at term pregnancy: report of one case. *Obs Gynecol* 1958;12(2):225–9.
- Velter C, Hotz C, Ingen-Housz-Oro S, Wolkenstein P, Fardet L. Stevens-Johnson syndrome during pregnancy: case report of a newborn treated with the culprit drug. *JAMA Dermatol* 2018;154(2):224–5.
- White KD, Abe R, Ardern-Jones M, Beachkofsky T, Bouchard C, Carleton B, et al. SJS/TEN 2017: Building multidisciplinary networks to drive science and translation. *J Allergy Clin Immunol Pract* 2018;6(1):38–69.
- Winston HG, Mastroianni Jr L. Stevens-Johnson syndrome in pregnancy. *Am J Obs Gynecol* 1954;67(3):673–6.
- Yanagida S. A case report of pregnancy associated with Stevens-Johnson syndrome at 16 weeks of gestation. *Acta Obs Gynecol Japan* 2002;52:943–7.
- Yang C, Mosam A, Mankahla A, Dlova N, Saavedra A. HIV infection predisposes skin to toxic epidermal necrolysis via depletion of skin-directed CD4+ T cells. *J Am Acad Dermatol* 2014;70(6):1096–102.