

UC Davis

Dermatology Online Journal

Title

Yellow hair following sequential application of bacitracin zinc and selenium sulfide: Report of acquired xanthotrichosis and review of yellow hair discoloration

Permalink

<https://escholarship.org/uc/item/9ft033d0>

Journal

Dermatology Online Journal, 22(6)

Authors

Crowley, Christopher S
Cohen, Philip R

Publication Date

2016

DOI

10.5070/D3226031315

Copyright Information

Copyright 2016 by the author(s). This work is made available under the terms of a Creative Commons Attribution-NonCommercial-NoDerivatives License, available at <https://creativecommons.org/licenses/by-nc-nd/4.0/>

Peer reviewed

Case Report

Yellow hair following sequential application of bacitracin zinc and selenium sulfide: Report of acquired xanthotrichosis and review of yellow hair discoloration

Christopher S. Crowley MD PhD, Philip R. Cohen MD

Dermatology Online Journal 22 (6): 3

Department of Dermatology, University of California San Diego, San Diego, CA

Correspondence:

Christopher S. Crowley MD PhD
8899 University Center Lane, Suite 350
San Diego, Ca 92122
Email: christophercrowl@gmail.com

Philip R. Cohen, MD
10991 Twinleaf Court
San Diego, CA 92131
Email: mitehead@gmail.com

Abstract

Background

Acquired yellow hair (xanthotrichosis) can result from the deposition of pigmented compounds on the hair shaft or from chemical modification of hair pigment and protein molecules.

Purpose

A white-haired 77-year-old woman who developed xanthotrichosis of her scalp hair following the sequential application of bacitracin zinc ointment and selenium sulfide 2.5% lotion is described and the causes of yellow hair discoloration are reviewed.

Materials and methods

The clinical features of a woman with acquired yellow hair discoloration are presented. Using PubMed and Google Scholar, the following terms were searched and relevant citations were assessed: bacitracin zinc, hair discoloration, selenium sulfide, xanthotrichosis, and yellow hair.

Results

Yellow hair was observed on the scalp in areas treated with the following regimen: prior to bedtime, several areas of the scalp were treated with a single application of bacitracin zinc ointment. The next morning, selenium sulfide 2.5% lotion was applied and then rinsed from the scalp during showering. Yellow hair discoloration was apparent in co-treated areas immediately following rinsing; the discoloration gradually faded over 2-5 days with regular shampooing.

Conclusions

Acquired yellow hair shaft discoloration has been reported secondary to multiple etiologies, including environmental and occupational exposures, iatrogenic causes (including topical and systemic drugs) and protein-calorie malnutrition. To this list, we add yellow discoloration of white scalp hair due to application of selenium sulfide following topical use of bacitracin zinc in the affected areas as an unexpected adverse effect that may occur in individuals with white hair.

Key words: bacitracin, discoloration, hair, selenium, sulfide, xanthotrichosis, yellow, zin

Introduction

Yellow hair discoloration (xanthotrichosis) is an uncommon and unusual presenting complaint, but merits consideration for an in-depth workup [1]. Indeed, yellow-to-blond hair discoloration can occur secondary to a diversity of etiologic factors, including harmful environmental and occupational exposures, drugs, or systemic disease. In many individuals, however, the cause of their hair discoloration is difficult to establish [2,3]. We describe a white-haired woman who developed temporary yellow hair discoloration after sequential use of bacitracin zinc ointment and selenium sulfide 2.5% lotion. We also review the causes of acquired yellowing of hair (Table 1) [1-23], as well as other hair changes reported in association with application of selenium sulfide lotion.

Table 1. Causes of yellow hair discoloration (xanthotrichia)

Setting	Source	
Environmental and occupational	Cigarette smoke [4-6]	
	Copper [7]	
	Dihydroxyacetone [8]	
	Hydrogen peroxide [9]	
	Hypochlorous acid [10]	
	Picric acid [11]	
	Resorcinol [12]	
	Sunlight exposure [13]	
	1 - naphthol derivatives [12]	
	4,4' methylenedianiline (MDA) [14]	
	Iatrogenic	Topical agents
Anthralin (acidic conditions) [15]		
Minoxidil 1.5% [16]		
Selenium sulfide (with/without bacitracin) [8,17,18]		
Tar shampoo [7]		
Systemic drugs		
Chloroquine [2]		
Cisplatin [2]		
Heptaminol [19]		
Mephesisin [2]		
Minoxidil [20]		
para-aminobenzoic acid [2]		
Sunitinib [2]		
Tamsulosin [3]		
Valproic acid [2]		
Systemic conditions		Essential fatty acid deficiency [21] ^a
		Malignancy (leiomyosarcoma) [22] ^a
	Protein-calorie malnutrition [1]	
	Vitamin B12 deficiency [23] ^a	

^a some of these etiologies can also result in lightening of the hair color

Case report

A 77-year-old, white-haired woman presented for evaluation and management of scalp irritation secondary to seborrhea and mild folliculitis. Her scalp treatment included application of bacitracin zinc ointment under a shower cap overnight, followed the next morning by an alternating regimen of anti-seborrheic shampoos using either selenium sulfide 2.5% lotion, tar shampoo (Neutrogena T/Gel) or ketoconazole 2% shampoo.

At her follow up visit, the patient complained of yellow scalp hair discoloration that only occurred on days following the use of selenium sulfide lotion. Cutaneous examination showed patches of orange-yellow hair, with white hair remaining in untreated areas (Figure 1).

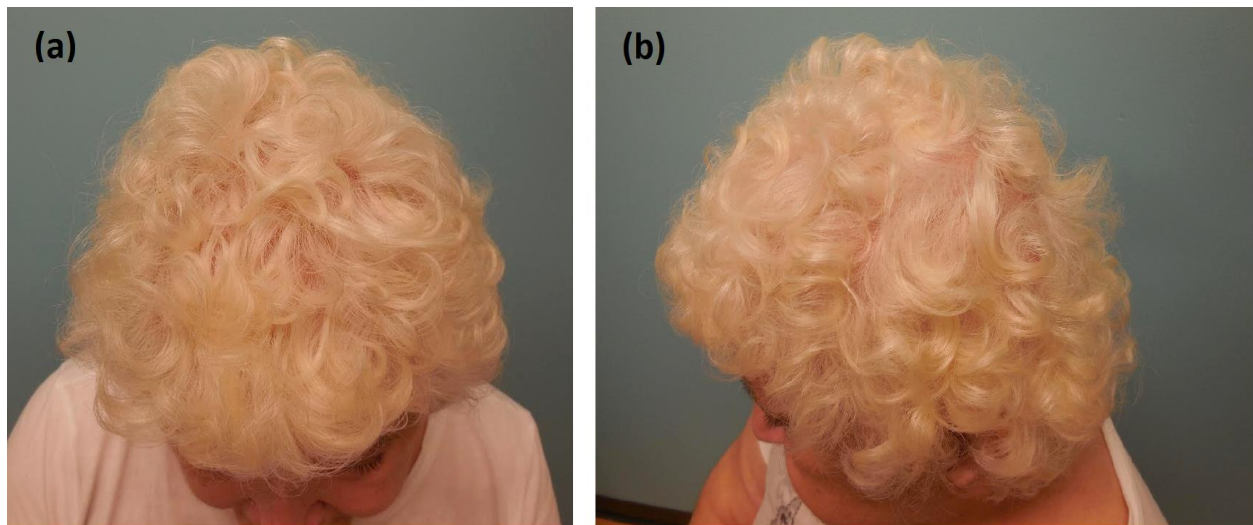

Figure 1. (a, and b). Front (a) and side (b) views of the acquired yellow scalp hair in a white-haired woman after application of bacitracin zinc in the evening followed by occlusion overnight under a shower cap, then subsequent shampooing of the hair with selenium sulfide lotion the following morning. The patient reported no new scalp symptoms occurring with discoloration.

The yellow hairs corresponded to the bacitracin zinc treated areas of her scalp. The patient also noted that the yellow pigment slowly faded with routine shampooing over the next 2 to 5 days, restoring her natural white hair color (Figure 2). She denied any additional associated symptoms, such as pruritus, and there was not any alopecia.

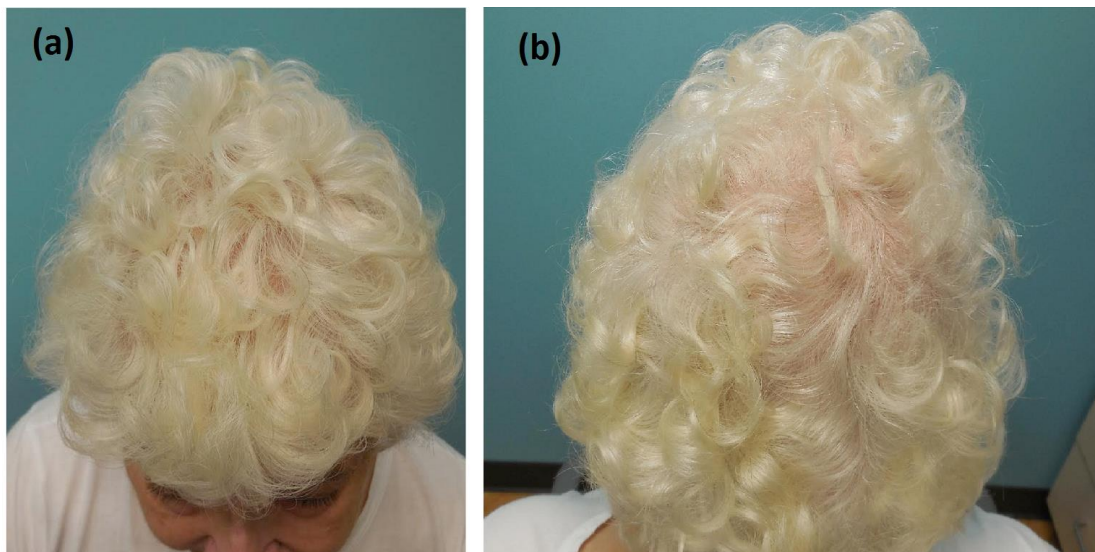


Figure 2. (a, and b). Front (a) and posterior (b) views of scalp in a white-haired woman showing restoration of normal appearing white hair. These images were obtained following 2-5 days of normal shampooing of previously yellow hair.

Detailed history also revealed that similar changes were absent on the days following the use of either the tar or ketoconazole containing shampoos, as well as on days without prior application of bacitracin zinc. There were no new medications and the patient does not smoke.

Aside from mild bemusement regarding her new hair color, the patient was otherwise asymptomatic. She appeared pleased after several other patients in the office waiting room complimented the appearance of her hair and inquired where she had her hair colored.

Discussion

We report a woman who developed temporary yellow discoloration of her naturally white scalp hair after sequential application of bacitracin zinc followed by selenium sulfide 2.5% lotion. Selenium sulfide exposure has been previously cited as a cause of temporary hair discoloration [8,17,18]. However, the combined use of bacitracin zinc has not been previously reported as a predisposing risk factor for these changes.

Selenium sulfide-associated hair discoloration

Selenium sulfide salt exists as an orange-brown powder with poor water solubility and is widely used as an antiseborrheic preparation [24]. Previous investigators have observed yellow, orange-to-red-brown and green hair discoloration with use of selenium sulfide containing scalp treatments, likely owing to selenium sulfide deposition on the hair shaft after repeated applications [8,17,18]. The discoloration may be pronounced if the applications are followed by inadequate rinsing [8]. The researchers have hypothesized that the structure of damaged hair, such as hair damaged due to sun exposure or concurrent tinea capitis, may be more susceptible to deposition of selenium sulfide because the selenium sulfide is easily trapped by the fragmented hair shafts [8]. In our patient, we speculate that excessive amounts of white petrolatum, the base ingredient in the bacitracin zinc ointment, may have trapped the relatively hydrophobic selenium sulfide on the hair shafts. Although the manufacturer's label for selenium sulfide lotion states that discoloration "can be avoided or minimized by thorough rinsing of hair after treatment," additional verbal precautions and instructions for thorough rinsing may be warranted when this product is prescribed.

Selenium sulfide-induced hair shaft discoloration has included yellow discoloration of an 86-year-old white-haired male [8], orange-to-red-brown discoloration in six children (whose ages ranged from 10 months to 8 years and for whom the initial hair colors were not described), [18], and green discoloration in a 4-year-old African-American child (in whom the initial hair color was not reported) [17]. In each individual, hair discoloration was only noted on the scalp, discoloration resolved soon after discontinuing use of selenium sulfide-containing products and no additional symptoms were reported in association with patients' hair color changes.

The observed color changes resulting from application of selenium sulfide varied, depending on the patient's initial hair color. Both white-haired patients, including our patient, developed yellow discoloration [8]. Alternatively, seven children developed hair colors ranging from orange to red-brown to green [17,18]. This range of discoloration is most likely the result of the variable appearance of yellow-orange selenium sulfide on different backgrounds of pigmented hair.

Etiology of xanthotrichosis

The causes of acquired lightening of hair color, resulting in yellow to blonde to orange-red discoloration, range from exogenous exposures to systemic metabolic alteration (Table 1). Exogenous factors resulting in xanthotrichosis include pigmented compounds that are inadvertently deposited on the hair shaft, including cigarette smoke residue [4-6], copper [7], dihydroxyacetone [8], MDA (4, 4' - methylenedianiline) [14], 1-naphthol [12], picric acid [11] and resorcinol (dihydroxybenzene) [12]. Topical medications may also result in yellow discoloration, including anthralin when applied under acidic conditions [15], minoxidil [16], and tar shampoo [7].

Chemical modification of hair shaft components, including melanin pigment molecules and keratin proteins, may also result in yellowing or lightening of hair. Permanent cosmetic hair dyes employ oxidizing agents, such as hydrogen peroxide, which oxidize melanin pigments and lighten hair color [9]. Lightening of swimmers' hair may occur as a result of oxidative degradation of melanosomes from hypochlorous acid in swimming pool water [10]. Sunlight exposure, likewise, denatures melanin [13]; sunlight additionally lightens hair color via photo-oxidation of keratin amino acid sidechains, causing a yellow tint in white-haired individuals [25].

Systemic causes of yellowing or lightening of hair color generally act by altering normal synthesis of melanin pigment molecules. Systemic medications are a common cause of hair color changes, and several have been implicated, including chloroquine, cisplatin, heptaminol, mephenesin, para-aminobenzoic acid (PABA), sunitinib, tamsulosin, and valproic acid [2,3,19,26]. Systemic processes known to cause lightening of hair color include metabolic or nutritional deficiencies (such as protein-calorie malnutrition-Kwashiorkor [1], essential fatty acid deficiency [21], and vitamin B12 deficiency [23]), and malignancy (leiomyosarcoma) [22]. Periodic, severe metabolic fluctuations as a result of diseases or medications may manifest as the "flag" sign, appearing as lightened horizontal bands of discolored hair interrupting lengths of normal hair [1].

Evaluation of individuals with yellow hair discoloration

Yellow hair discoloration may occasionally be a patient's chief complaint. The differential diagnosis is broad and involves exogenous and systemic factors. The initial history should focus on identifying workplace exposures, hobbies, new medications, smoking history; a careful review of systems, noting any symptoms of systemic pathology is essential. All medications should be reviewed as well, including over-the counter medications and supplements.

A thorough physical exam should be performed, noting the distribution of discolored hair, additional discoloration of the skin or nails, and signs of systemic disease. An occupational cause of yellow discoloration, for example, may be suspected by a staining pattern involving exposed areas such as the eyebrows and frontal-temporal regions of the scalp [11,14]. Smokers often have yellowed patches in smoke-exposed areas, including mustaches and the frontal scalp [4-6]. Exogenous sources of yellow pigment may be detected by rubbing discolored hair with an alcohol swab, which may remove the deposited residue [18].

In many patients, despite a thorough workup, no definitive cause of discoloration is discovered [3]. For these individuals, the follow up plan requires careful, intuitive judgement. Regularly scheduled follow up or referral is indicated if an occult pathologic process is suspected. In apparently indolent cases, the psychosocial impact should be assessed; distressed patients, for example, can be offered a more extensive workup, including substitution of their medications. Consultation with a beautician for hair dyeing may provide additional comfort as well.

Conclusion

Hair discoloration secondary to selenium sulfide 2.5%, albeit uncommon, has been described. We report a unique circumstance in which acquired xanthotrichosis developed in a 77-year-old white-haired woman following sequential use of bacitracin zinc and selenium sulfide 2.5% lotion; the woman's normal white hair color was restored 2-5 days after discontinuing use of selenium sulfide. Yellowed or lightened discoloration commonly occurs secondary to medications, but environmental, occupational, topical medications, and metabolic alterations may additionally be the cause. A detailed medication history may be helpful to elucidate the etiology of acquired yellow hair discoloration.

References

1. Cline DJ. Changes in hair color. *Dermatol Clin*. 1988; 6: 295-303. [PMID: 3288386].
2. Bublin JG, and Thompson DF. Drug-induced hair colour changes. *J Clin Pharm Ther*. 1992; 17: 297-302. [PMID: 1464633].
3. Martí Fajardo N, García Llopis P, Ibáñez Ramón R, Ortega Monzó C. Probable iatrogenic xanthotrichia. *Actas Dermosifiliogr*. 2014; 105: 722-3. [PMID: 25181953].
4. Kellen RI, Schrank B, Burde RM. Yellow forelock--a new neuro-ophthalmological sign. *Br J Ophthalmol*. 1990; 74: 509-10. [PMID: 2390530].
5. Dimmick JR and Wagner RF Jr. A patient with smoker's mustache. *Res Staff Phys*. 2006; 52 (4): 23-25. (No PMID).
6. Beutler BD and Cohen PR. Tobacco-associated yellow discoloration of upper lip hair: smoker's mustache. *Dermatol Online J*. 2015; 21(5)2. (PMID 26295850).
7. Smith ML: Chapter 88 – Environmental and Sports-related Diseases, Disorders due to physical agents, Chemical hair discoloration. In: *Dermatology*, Edited by Bologna JL, Lorizzo, JL, Rapini, RP, 1st Edition. Edinburgh, London, New York, Oxford, Philadelphia, St. Louis, Sydney, Toronto, Mosby: 2003; 1385-1409.
8. Prevost N, English JC 3rd. Xanthotrichia (yellow hair) due to selenium sulfide and dihydroxyacetone. *J Drugs Dermatol*. 2008; 7: 689-91. [PMID: 18664164].
9. Wolfram LJ, Hall K, Hui I. The mechanism of hair bleaching. *J Soc Cosmet Chem*. 1970; 21: 875-900. (No PMID).
10. Nanko H, Mutoh Y, Atsumi R, Kobayashi Y, Ikeda M, Yoshikawa N, Fukuda S, Kawa Y, Mizoguchi M. Hair-discoloration of Japanese elite swimmers. *J Dermatol*. 2000; 27: 625-34. [PMID: 11092265].
11. Sunderman FW, Weidman FD, Batson OV. Studies of the effects of ammonium picrate on man and certain experimental animals. *J Ind Hyg Toxicol*. 1945; 27: 241-8. [PMID: 21007118].
12. Jackson GT and McMurtry CW. Chapter IV. Canities - Discoloration of the hair. Discoloration of the hair. In: *A Treatise on Diseases of the Hair*. Philadelphia and New York. Lea & Febiger, 1912: 68-72.
13. Santos Nogueira AC, Joeques I. Hair color changes and protein damage caused by ultraviolet radiation. *J Photochem Photobiol B*. 2004; 74: 109-17. [PMID: 15157906].
14. Cohen SR. Yellow staining caused by 4,4'-methylenedianiline exposure. Occurrence among molded plastics workers. *Arch Dermatol*. 1985; 121: 1022-7. [PMID: 4026338].

17. Rogers MJ, Whitefield M, Marks VJ. Yellow hair discoloration due to anthralin. *J Am Acad Dermatol*. 1988; v19: 370-1. [PMID: 3170808].
18. Rebora A, Guarrera M. Hair discoloration caused by minoxidil lotion. *J Am Acad Dermatol*. 1989; 21: 1314. [PMID: 2584470].
19. Fitzgerald EA, Purcell SM, Goldman HM. Green hair discoloration due to selenium sulfide. *Int J Dermatol*. 1997; 36: 238-9. [PMID: 9159020].
20. Gilbertson K, Jarrett R, Bayliss SJ, Berk DR. Scalp discoloration from selenium sulfide shampoo: a case series and review of the literature. *Pediatr Dermatol*. 2012; 29: 84-8. [PMID: 21453309].
21. Gharibi L, Zouhair K, Ramdani B, Benchikhi H. Hair lightening in an hemodialysis patient treated by heptaminol (heptamyl). *Dermatol Online J*. 2009; 15: 16. [PMID: 19450409].
22. Traub YM, Redmond DP, Rosenfeld JB, McDonald RH Jr, Shapiro AP. Treatment of severe hypertension with minoxidil. *Isr J Med Sci* 1975; 11: 991-8. [PMID: 346].
23. Skolnik P, Eaglstein WH, Ziboh VA. Human essential fatty acid deficiency: treatment by topical application of linoleic acid. *Arch Dermatol*. 1977; 113: 939-41. [PMID: 406855].
24. Farrell AM, Ross JS, Thomas JM, Fisher C, Bunker CB. Acquired ichthyosis, alopecia and loss of hair pigment associated with leiomyosarcoma. *J Eur Acad Dermatol Venereol*. 1998; 10: 159-63. [PMID: 9553915].
25. Carmel R. Hair and fingernail changes in acquired and congenital pernicious anemia. *Arch Intern Med*. 1985; 145: 484-5. [PMID: 3977516].
26. "Selenium Disulfide." PubChem Open Chemistry Database. National Center for Biotechnology Information, n.d. <http://pubchem.ncbi.nlm.nih.gov/compound/Selenium_disulfide#section=Computed-Properties>, accessed 28 June, 2015.
27. Richena M, Silveira M, Rezende CA, Joekes I. Yellowing and bleaching of grey hair caused by photo and thermal degradation. *J Photochem Photobiol B*. 2014; 138: 172-81. [PMID: 24937436].
28. Vignand-Courtin C, Martin C, Le Beller C, Mateus C, Barbault-Foucher S, Rieutord A. Cutaneous side effects associated with sunitinib: an analysis of 8 cases. *Int J Clin Pharm*. 2012; 34: 286-9. [PMID: 22427001].