

UC Davis

Dermatology Online Journal

Title

Pemphigus foliaceus in a patient with gastrointestinal stromal tumor treated with adjuvant imatinib mesylate

Permalink

<https://escholarship.org/uc/item/9n18x89m>

Journal

Dermatology Online Journal, 26(6)

Authors

Lewis, Hal A
Chen, David Y
Rosman, Ilana S
et al.

Publication Date

2020

DOI

10.5070/D3266049324

Copyright Information

Copyright 2020 by the author(s). This work is made available under the terms of a Creative Commons Attribution-NonCommercial-NoDerivatives License, available at <https://creativecommons.org/licenses/by-nc-nd/4.0/>

Peer reviewed

Pemphigus foliaceus in a patient with gastrointestinal stromal tumor treated with adjuvant imatinib mesylate

Hal A Lewis¹ MD, David Y Chen¹ MD PhD, Ilana S Rosman^{1,2} MD, Joel Picus³ MD, Milan J Anadkat¹ MD

Affiliations: ¹Division of Dermatology, Department of Medicine, Washington University School of Medicine, Saint Louis, Missouri, USA, ²Department of Pathology and Immunology, Washington University School of Medicine, Saint Louis, Missouri, USA, ³Division of Oncology, Department of Medicine, Washington University School of Medicine, Saint Louis, Missouri, USA

Corresponding Author: Milan Anadkat MD, 660 South Euclid Avenue, Campus Box 8123, Saint Louis, MO 63110, Tel: 314-362-9859, Email: manadkat@dom.wustl.edu

Abstract

Pemphigus is an autoimmune bullous disease with a number of described associations, including medications, which have been grouped into three structural categories — thiol drugs, phenol drugs, and drugs with neither functional group [1]. Discontinuation of the offending medication is considered a mainstay of therapy. We report a patient in whom the onset of pemphigus foliaceus was associated with initiation of imatinib mesylate adjuvant therapy in a patient with resected gastrointestinal stromal tumor (GIST). Imatinib was continued because of the survival benefit to the patient with a resected, high risk GIST. Treatment with rituximab resulted in near resolution of his blistering rash and follow up enzyme-linked immunosorbent assay (ELISA) demonstrated reference range immunoreactivity for both desmoglein 1 and desmoglein 3. After dose increase of imatinib therapy owing to tumor growth, the patient subsequently again developed a similar eruption. Re-biopsy and ELISA were consistent with recurrence of pemphigus. In conclusion, although the patient's pemphigus was cleared with a single cycle of rituximab infusions while continuing imatinib therapy, the disease returned after imatinib dose was increased a year later, suggesting a dose-response relationship.

Keywords: pemphigus foliaceus, drug reactions, chemotherapy

Introduction

Pemphigus is an autoimmune blistering disease often associated with specific medications. Discontinuation of the offending medication is

considered the treatment of choice. Management of medication associated pemphigus can be difficult when the associated medication is vital to a patient's survival. We report a patient in whom the onset of pemphigus foliaceus was associated with imatinib mesylate therapy in a patient with resected gastrointestinal stromal tumor (GIST). Imatinib was continued because of the survival benefit to the patient. Treatment with rituximab resulted in near resolution of his blistering rash; however, the disease returned after imatinib dose was increased a year later, suggesting a dose-response relationship.

Case Synopsis

An 80-year-old man diagnosed with an 11cm, c-kit-positive gastrointestinal stromal tumor (GIST) with a

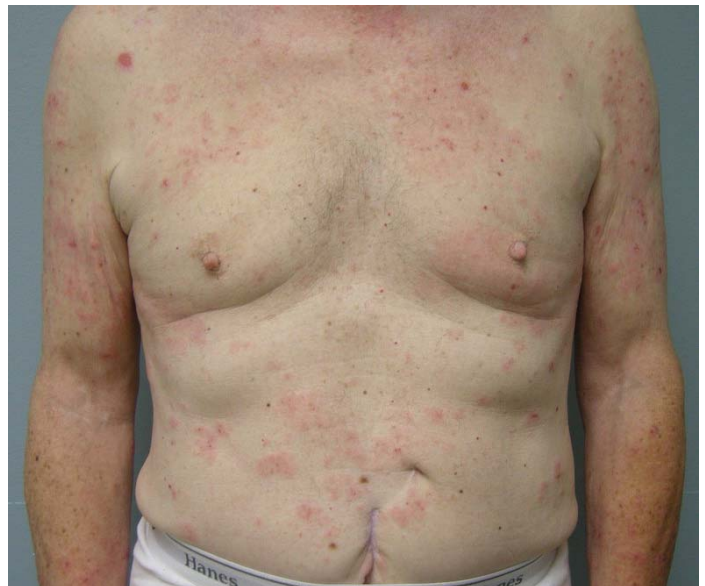

Figure 1. Initial presentation with erythematous, edematous and eroded papules and plaques scattered on the trunk and reaching confluence on the upper arms. With topical therapy and phototherapy, this eruption resolved.

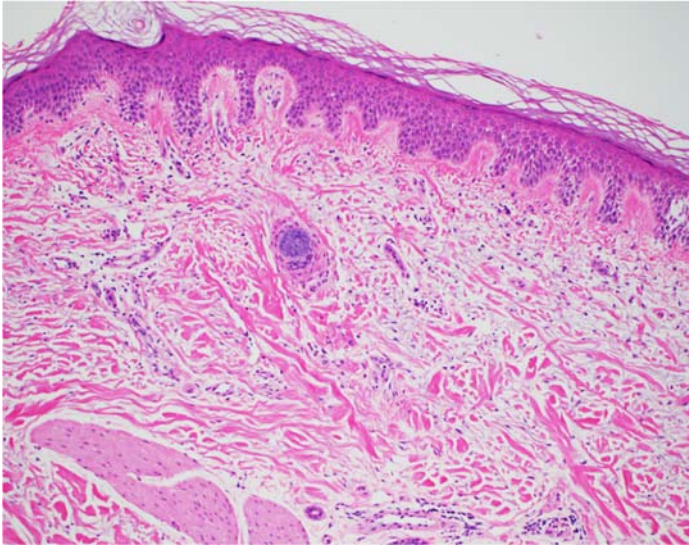


Figure 2. Punch biopsy of the skin at initial presentation demonstrating superficial perivascular inflammatory infiltrate with eosinophils. H&E, 100x.

high mitotic rate in the small bowel was subsequently treated with resection and adjuvant imatinib mesylate at a dose of 400mg daily. A few weeks after treatment initiation, he developed mild periorbital and lower extremity swelling with pruritus which subsided over the ensuing months. He then developed a whole body, pruritic eruption of pink, edematous plaques, small vesicles and tense bullae, and erosions 11 months after initiating imatinib therapy (**Figure 1**). Punch biopsy demonstrated superficial perivascular dermatitis with lymphocytes, histiocytes, and rare eosinophils consistent with a drug eruption (**Figure 2**). Direct immunofluorescence examination at this time was negative. The patient was treated with an oral prednisone taper over two weeks and a topical regimen of tacrolimus ointment to face, triamcinolone ointment to the body, and clobetasol ointment to worst areas, which resulted in improvement but incomplete clearance. He subsequently initiated narrow band ultraviolet B therapy three times weekly and underwent 27 treatments with complete clearance of his rash. Phototherapy was decreased to once weekly, resulting in recrudescence of the eruption six weeks after tapering narrow band ultraviolet B therapy (**Figure 3**).

At this time (approximately 18 months after initiation of imatinib therapy), a second biopsy demonstrated

intraepidermal vesicular and spongiotic dermatitis with eosinophils, whereas direct immunofluorescence was positive for intercellular IgG and C3 fluorescence within the epidermis (**Figure 4**). Enzyme-linked immunosorbent assay (ELISA) demonstrated elevated reactivity to desmoglein 1 (55.95, reference <14) and reference-range reactivity to desmoglein 3 (3.14, reference <9) consistent with

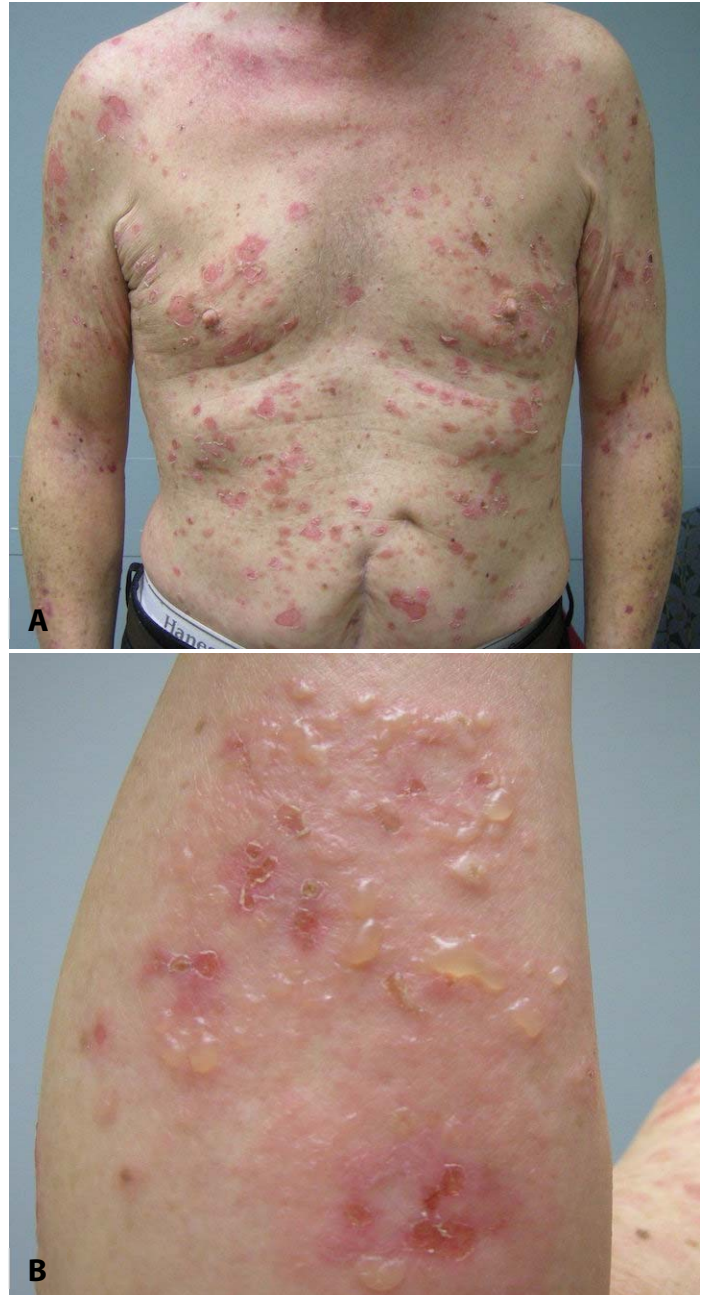

Figure 3. A) Tapering of phototherapy resulted in recurrence of the rash with more prominent erythematous, edematous plaques, tense vesicles and bullae, and erosions on the chest. **B)** Erythematous edematous plaques with tense bullae and erosions on the forearm.

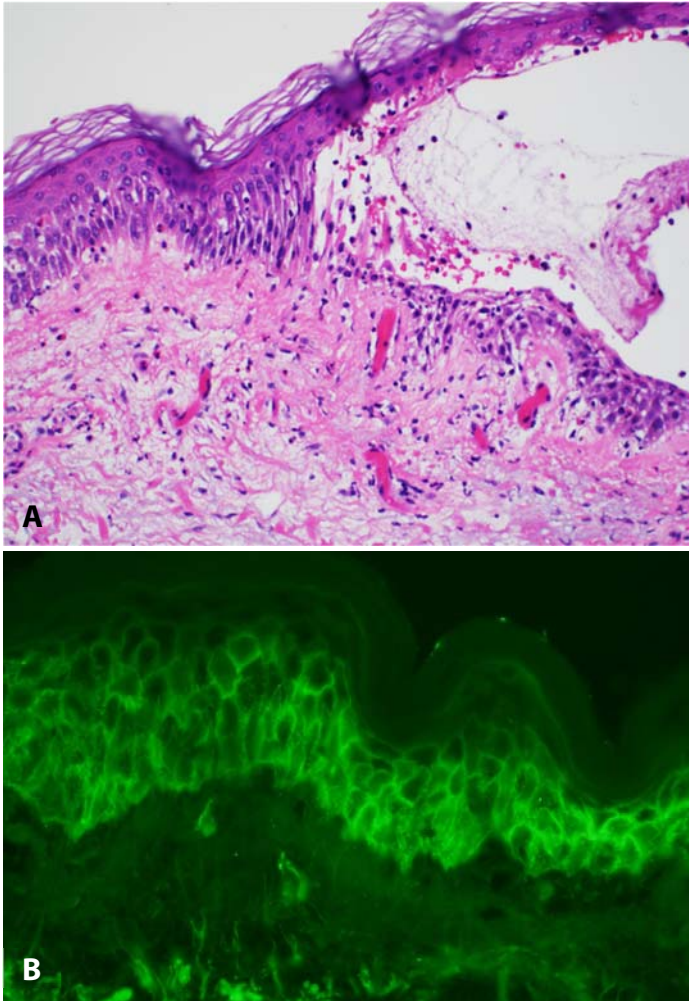


Figure 4. A) Punch biopsy of the skin at relapse with clinical bullae demonstrating spongiosis, intraepidermal vesiculation, and eosinophils. H&E, 200 \times . **B)** Corresponding direct immunofluorescence of punch biopsy of skin at relapse showing positive intercellular C3 reactivity on examination, 400 \times .

pemphigus foliaceus. Treatment with two doses of rituximab at 1000mg administered intravenously spaced two weeks apart resulted in marked improvement two months after therapy and near resolution of his blistering rash five months after therapy (**Figure 5**). Follow up ELISA two months after rituximab infusion demonstrated reference range immunoreactivity for both desmoglein 1 and desmoglein 3. Imatinib was continued throughout rituximab therapy to achieve three years of total treatment (stopped in June 2016).

Unfortunately, the patient was found to have recurrence of his GIST approximately one year after imatinib discontinuation. He was restarted on imatinib therapy at the same dose of 400mg daily in

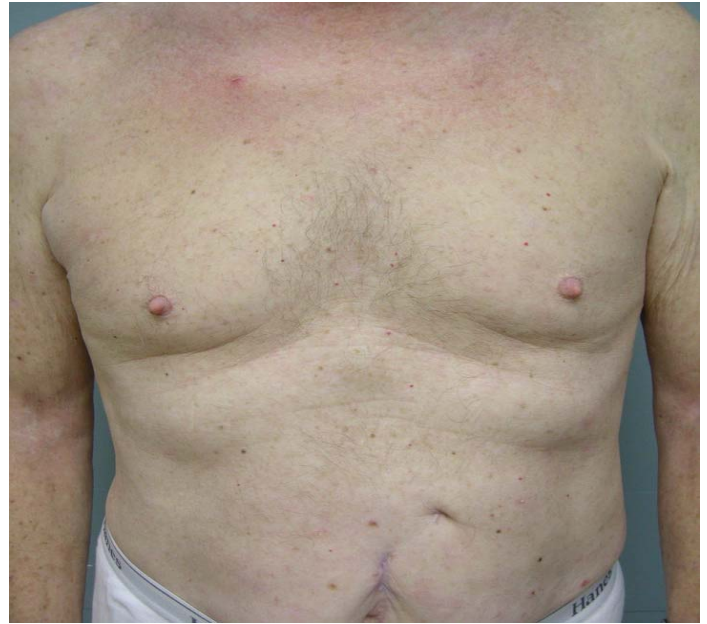

Figure 5. Clinical remission was achieved five months after one cycle of two rituximab infusions.

July 2017, with the plan to keep patient on therapy long term per medical oncology. The patient noticed periorbital edema soon after restarting therapy and mild recurrence of rash, specifically a few isolated erosions and edematous papules on scalp and back, adequately managed with topical corticosteroids 6 months after reinitiating therapy. Owing to progression of his cancer on 400mg daily of imatinib, the dosage was increased to 800mg daily in September 2018. A few weeks after this dose increase, the patient noticed worsening and was seen in dermatology clinic. At that time, he was found to have numerous scattered annular urticaria-like plaques on the back and upper arms (**Figure 6A**). Punch biopsy of one of the annular lesions showed focal intraepidermal vesiculation with acantholysis (**Figure 6B**) and once again, ELISA demonstrated elevated reactivity to desmoglein 1 (27.25, reference<14) and reference-range reactivity to desmoglein three (0.47 reference<9) consistent with recurrence pemphigus foliaceus. Of note, the histopathology findings in this case were not specific to pemphigus foliaceus but are compatible with the disease when taken together with the direct immunofluorescence and ELISA findings.

The patient has history of prostate cancer surgically resected 9 years prior to his presentation and

superficial urothelial cell bladder cancer treated with intravesical Bacillus Calmette-Guerin (BCG) therapy with recurrence and additional BCG therapy at the time of this report. His chronic medications included aspirin and levothyroxine.

Case Discussion

Imatinib mesylate was initially described as a clinically effective inhibitor of the oncogenic BCR-ABL fusion kinase in chronic myelogenous leukemia and Philadelphia chromosome-positive acute lymphoblastic leukemia [2-4]. At the same time, it was shown to have an anti-tumor effect in metastatic GIST related to the cross inhibition of the tyrosine kinase c-kit [5]. Imatinib mesylate used in the adjuvant setting for resected GIST has demonstrated improved relapse-free survival and longer term treatment yields with better five-year survival [5, 6]. In general, imatinib therapy is well tolerated, though edema and rashes are frequently seen in a dose-dependent fashion [3, 4, 7]. One prospective study characterized the majority of rashes as exanthematous or maculopapular eruptions, and less commonly severe exfoliative dermatitis, pustular eruption, and psoriasiform plaques [7]. Other manifestations reported include lichenoid rash, acute generalized exanthematous pustulosis, and Stevens-Johnson syndrome [8-11].

Our patient exhibited the common cutaneous manifestation of periorbital and lower extremity edema. The temporal relationship between the onset of pemphigus foliaceus and the initiation of imatinib is circumstantially suggestive of a causal relationship. Although imatinib mesylate does not contain a thiol group like other better characterized causes of drug-induced pemphigus, it is a methanesulfonate salt that does coordinate the thiol group in a critical methionine residue in the nucleotide binding pocket of the Abelson kinase [2]. The pathogenesis of thiol drug-mediated pemphigus is not known, though postulated mechanisms include direct, drug-induced acantholysis, upregulation of acantholytic enzymes like plasminogen activator, and neoantigen formation [1, 12, 13].

Aside from the temporal relationship between imatinib therapy initiation and the onset of pemphigus foliaceus, other characteristics of this presentation suggest a drug-related etiology rather than this representing a case of coincident idiopathic pemphigus foliaceus. The preceding eruption was typical of a drug-induced hypersensitivity eruption, and it responded very well to typical therapies for

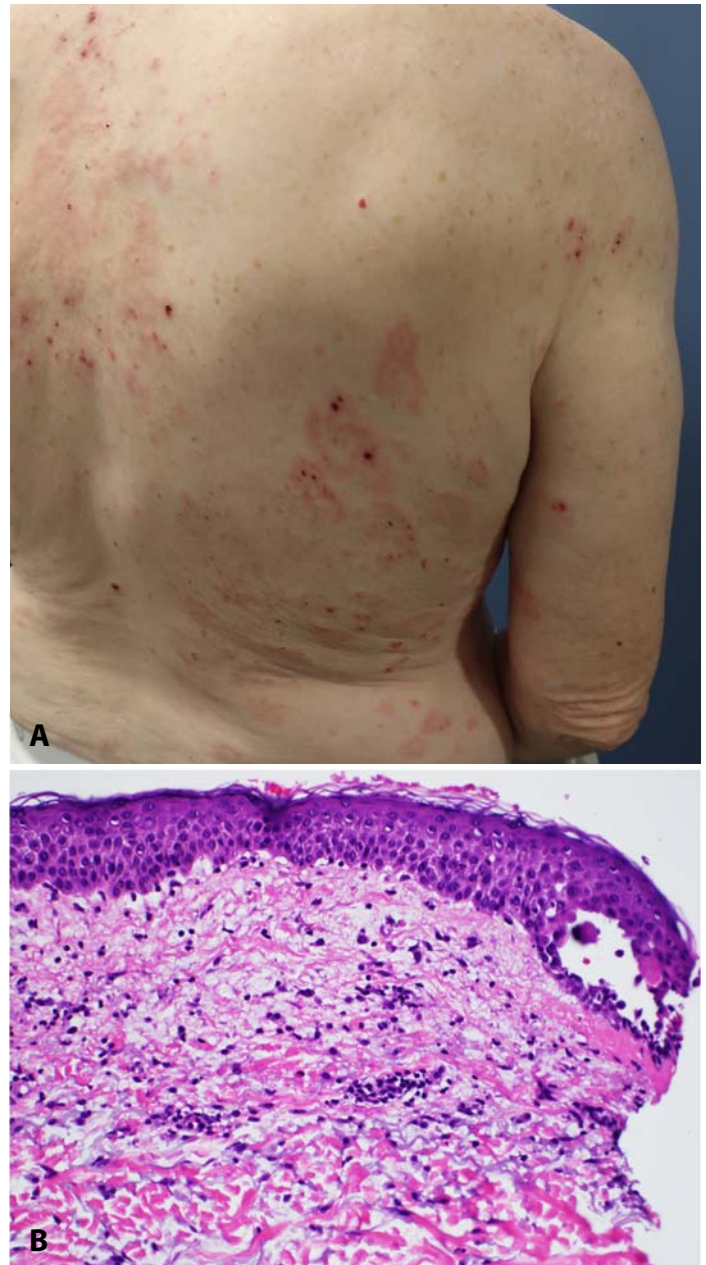


Figure 6. A) Scattered annular urticaria-like plaques on the back and upper arms. **B)** Punch biopsy of the skin of the left back after rash recurrence shows mild spongiosis, focal intraepidermal acantholysis, and a mixed inflammatory infiltrate with eosinophils. H&E, 200x.

hypersensitivity, including narrow band UVB phototherapy and topical corticosteroid therapies. The hypersensitivity eruption subsequently gave way to a bullous dermatosis with features not typical for idiopathic pemphigus foliaceus, including grouped, tense bullae in an annular configuration. In a recent case series of patients with drug-induced pemphigus, 16 of 17 were induced by thiol drugs, yet the phenotype of blistering disorder was variable despite the well-defined causes. The predominant type was that of classic pemphigus foliaceus, though there were a few cases of pemphigus herpetiformis type as well as unclassified types [13]. The case presented in this report certainly does not fit classic, idiopathic pemphigus foliaceus, though the phenotype of idiopathic pemphigus foliaceus with concomitant imatinib therapy is not known.

Of note, a form of pemphigus — paraneoplastic pemphigus — is associated with certain malignancies such as non-Hodgkin lymphoma, chronic lymphocytic leukemia, and Castleman disease [14]. It is possible that the flaring of pemphigus in our patient could have been related to tumor recurrence rather than treatment. However, paraneoplastic pemphigus is characterized clinically by oral erosions often followed by polymorphic cutaneous disease and systemic manifestations [15]. The histopathology varies based on the type of skin lesions and direct immunofluorescence can show linear C3 and IgG deposits at the epidermal-dermal junction [16]. In addition, immunopathology can demonstrate antibodies to desmoglein 3, desmoplakin 1, BP230, desmoplakin 2, envoplakin, plectin, and epiplakin [17]. Paraneoplastic pemphigus has been associated with GIST [18]. However, our patient's clinical and immunopathological manifestations were compatible with pemphigus foliaceus rather than paraneoplastic pemphigus.

It is important to note that the highly morbid skin disease in this patient did respond well to rituximab

therapy. This allowed the continuation of adjuvant imatinib therapy for this patient whose tumor had a high risk of recurrence. Recent data demonstrates that three years of imatinib therapy in high risk GIST is superior to one year of therapy in both recurrence-free survival at five years and overall survival [19].

To our knowledge, only one other case in the literature demonstrated imatinib-associated pemphigus foliaceus. However, in this case, imatinib was discontinued and treatment with prednisolone and azathioprine facilitated the resolution of the patient's pemphigus. One month after reintroduction of imatinib, pemphigus recurred in this reported patient leading to indefinite discontinuation of imatinib [20].

Conclusion

Our case supports the observation that imatinib may induce pemphigus foliaceus, further confirmed by the development of this phenotype on two separate occasions, both after therapy initiation and dose increase. Most importantly, this case demonstrates that targeted therapy, specifically with rituximab, treats this imatinib toxicity and allows for continuation of anticancer therapy in high risk patients.

Potential conflicts of interest

Dr. Anadkat has served as a consultant for Abbvie, Adgero, Biogen, Boehringer-Ingelheim, Innovaderm, NovoCure, OnQuality, Eli Lilly, and UCB Biopharma. He has received honoraria in the past as a speaker for ImClone, Bristol Myers Squibb, Therakos, Eisai, and Biogen. He has also served as a Principal Investigator for Abbvie, Hana Biosciences, Xoma, InflamRx, Biogen, Lutris, AnaptysBio, Boehringer-Ingelheim, OnQuality, Veloce, Novartis, ChemoCentryx, UCB Biopharma, Eli Lilly, and XBiotech.

References

1. Brenner S, Goldberg I. Drug-induced pemphigus. *Clin Dermatol*. 2011;29:455–457. [PMID: 21679874].
2. Schindler T, Bornmann W, Pellicena P, et al. Structural Mechanism for STI-571 Inhibition of Abelson Tyrosine Kinase. *Science*. 2000;289:1938–1942. [PMID: 10988075].
3. Druker BJ, Talpaz M, Resta DJ, et al. Efficacy and safety of a specific inhibitor of the BCR-ABL tyrosine kinase in chronic myeloid leukemia. *N Engl J Med*. 2001;344:1031–1037. [PMID: 11287972].
4. Druker BJ, Sawyers CL, Kantarjian H, et al. Activity of a specific inhibitor of the BCR-ABL tyrosine kinase in the blast crisis of

- chronic myeloid leukemia and acute lymphoblastic leukemia with the Philadelphia chromosome. *N Engl J Med*. 2001;344:1038–1042. [PMID: 11287973].
5. Joensuu H, Roberts PJ, Sarlomo-Rikala M, et al. Effect of the tyrosine kinase inhibitor STI571 in a patient with a metastatic gastrointestinal stromal tumor. *N Engl J Med*. 2001;344:1052–1056. [PMID: 11287975].
 6. Dematteo R, Ballman K, Antonescu C, et al. Adjuvant imatinib mesylate after resection of localised, primary gastrointestinal stromal tumour: a randomised, double-blind, placebo-controlled trial. *Lancet*. 2009;373:1097–1104. [PMID: 19303137].
 7. Valeyrie L, Bastuji-Garin S, Revuz J, et al. Adverse cutaneous reactions to imatinib (STI571) in Philadelphia chromosome-positive leukemias: A prospective study of 54 patients. *J Am Acad Dermatol*. 2003;48:201–206. [PMID: 12582389].
 8. Brouard MC, Prins C, Mach-Pascual S, Saurat JH. Acute Generalized Exanthematous Pustulosis Associated with STI571 in a Patient with Chronic Myeloid Leukemia. *Dermatology*. 2001;203:57–59. [PMID: 11549802].
 9. Hsiao L, Chung H, Lin J, et al. Stevens–Johnson syndrome after treatment with STI571: a case report. *Br J Haematol*. 2002;117:620–622. [PMID: 12028031].
 10. Lim DS, Muir J. Oral lichenoid reaction to imatinib (STI 571, Gleevec). *Dermatology*. 2002;205:169–171. [PMID: 12218235].
 11. Amitay-Laish I, Stemmer SM, Lacouture ME. Adverse cutaneous reactions secondary to tyrosine kinase inhibitors including imatinib mesylate, nilotinib, and dasatinib. *Dermatol Ther*. 2011;24:386–395. [PMID: 21910796].
 12. Ruocco, Angelis D, Lombardi. Drug-induced pemphigus. II. Pathomechanisms and experimental investigations. *Clin Dermatol*. 1993;11:507–513. [PMID: 8124640].
 13. Yoshimura K, Ishii N, Hamada T, et al. Clinical and immunological profiles in 17 Japanese patients with drug-induced pemphigus studied at Kurume University. *Br J Dermatology*. 2014;171:544–553. [PMID: 24588203].
 14. Kaplan I, Hodak E, Ackerman L, et al. Neoplasms associated with paraneoplastic pemphigus: a review with emphasis on non-hematologic malignancy and oral mucosal manifestations. *Oral Oncol*. 2004;40:553–62. [PMID: 15063382].
 15. Wieczorek M, Czernik A. Paraneoplastic pemphigus: a short review. *Clin Cosmet Invest Dermatol*. 2016;9:291–295. [PMID: 27729809].
 16. Tsuchisaka A, Kawano H, Yasukochi A, et al. Immunological and statistical studies of anti-BP180 antibodies in paraneoplastic pemphigus. *J Invest Dermatol*. 2014;134:2283–2287. [PMID: 24658507].
 17. Tsuchisaka A, Numata S, Teye K, et al. Epiplakin Is a Paraneoplastic Pemphigus Autoantigen and Related to Bronchiolitis Obliterans in Japanese Patients. *J Invest Dermatol*. 2016;136:399–408. [PMID: 26802236].
 18. Masu T, Okuyama R, Tsunoda T, et al. Paraneoplastic pemphigus associated with malignant gastrointestinal stromal tumour. *Acta Derm Venereol*. 2010;90:89–90. [PMID: 20107737].
 19. Joensuu H, Eriksson M, Hall K, et al. One versus Three Years of Adjuvant Imatinib for Operable Gastrointestinal Stromal Tumor: A Randomized Trial. *JAMA*. 2012;307:1265–1272. [PMID: 22453568].
 20. Chen WS, Chen YJ, Yang CS, Juan CK. Pemphigus foliaceus associated with imatinib therapy in a patient with gastrointestinal stromal tumor. *Int J Dermatol*. 2018;57:e93–e95. [PMID: 29993121].